

FIELDIANA • ZOOLOGY

Published by

CHICAGO NATURAL HISTORY MUSEUM

Volume 39

APRIL 21, 1958

No. 13

TARSAL LIGAMENTS OF THE SPECTACLED BEAR

Tremarctos ornatus

D. DWIGHT DAVIS

CURATOR, DIVISION OF VERTEBRATE ANATOMY

Among the Carnivora the tarsal ligaments have been described for the domestic dog (Baum and Zietzschmann, 1936) and the domestic cat (Reighard and Jennings, 1901). In both these forms the limbs are greatly modified for cursorial locomotion; the tarsus and metatarsus are elongated and immobilized, and the tarsal ligaments are reduced to little more than collateral ligaments. The structure and mechanics of the ankle and foot differ greatly from those of the generalized ferungulates, such as the Paleocene *Claenodon*, that were supposedly ancestral to the modern Carnivora.

The bears, in contrast, are plantigrade walkers and the bones of the tarsus do not differ significantly from those of *Claenodon*. The foot of the bears closely approximates, in fact, the primitive condition from which were derived the various specialized conditions found among modern carnivores and ungulates. It is impossible to understand the mechanics of the tarsus without a knowledge of the tarsal ligaments, and these ligaments in the bears are therefore of considerable interest. It is remarkable that they have never been examined.

This description is based on the South American spectacled bear, *Tremarctos ornatus*. The animal dissected was an adult female that died in the Zoo in Brookfield, Illinois, and was embalmed for anatomical study. The tarsal bones of *Tremarctos* are similar to those of other bears except that they are somewhat less broadened; in this respect they approach the primitive condition even more closely than does *Ursus*. An X-ray of the specimen before dissection, and the articulated bones of the tarsus and metatarsus of a second individual of the same species, along with the tarsal bones of other species of bears, of other carnivores, and of the fossil *Claenodon*

Library of Congress Catalog Card Number: 58-9928

No. 838

91

MAY 1 1958

NATURAL
HISTORY SURVEY
LIBRARY

Y 7 1958

corrugatus, were referred to constantly during the dissection. Comparisons were made with the tarsal ligaments of man as described and figured in standard textbooks and atlases. The nomenclature of human anatomy has been used wherever possible except that the term *astragalus*, customarily used in comparative anatomy, is used in preference to *talus*. To avoid unnecessary confusion in the names of ligaments, *talus* has been retained as a combining form.

The drawings illustrating this paper were made by Miss Phyllis Wade, Assistant in the Division of Anatomy, directly from the dissections. Thanks are due the American Museum of Natural History for the loan of a specimen of *Claenodon corrugatus* (AM no. 16543).

THE TALOCRURAL ARTICULATION

Only five ligaments are involved in this joint, compared with the seven present in man. The anterior calcaneotibial and tibionavicular ligaments are not represented in the bear; in man these are both on the medial side of the tarsus. The remaining five ligaments are essentially as in man.

The *posterior talofibular ligament* is a strong band, circular in cross section, running diagonally downward and mesad from the posterior border of the lateral malleolus to the posterior surface of the astragalus just above the groove for the flexor hallucis longus tendon.

The *anterior talofibular ligament* (fig. 12) is a slender band arising from the antero-inferior border of the malleolus of the fibula, deep to the part of the anterior lateral malleolar ligament that passes to the talofibular meniscus (see below). The ligament runs diagonally distally and medially across the astragalus, attaching to the superior surface of the neck of the astragalus immediately behind the talocuneiform articulation. A few of its fibers continue distad beyond this attachment, to attach to the superior surface of the second cuneiform together with the dorsal talonavicular ligament.

The *calcaneofibular ligament* (fig. 12) is a strong band of fibers extending from the calcaneus above and behind the posterior end of the trochlear process to a well-marked area on the distal end of the fibula immediately anterior to the malleolar groove. The fibers along the inferior border of the ligament pass onto the talofibular meniscus.

The deltoid ligament differs considerably from that of man. Only two of the four elements are represented in the bear; the longer pair of ligaments (the calcaneotibial and tibionavicular) are entirely want-

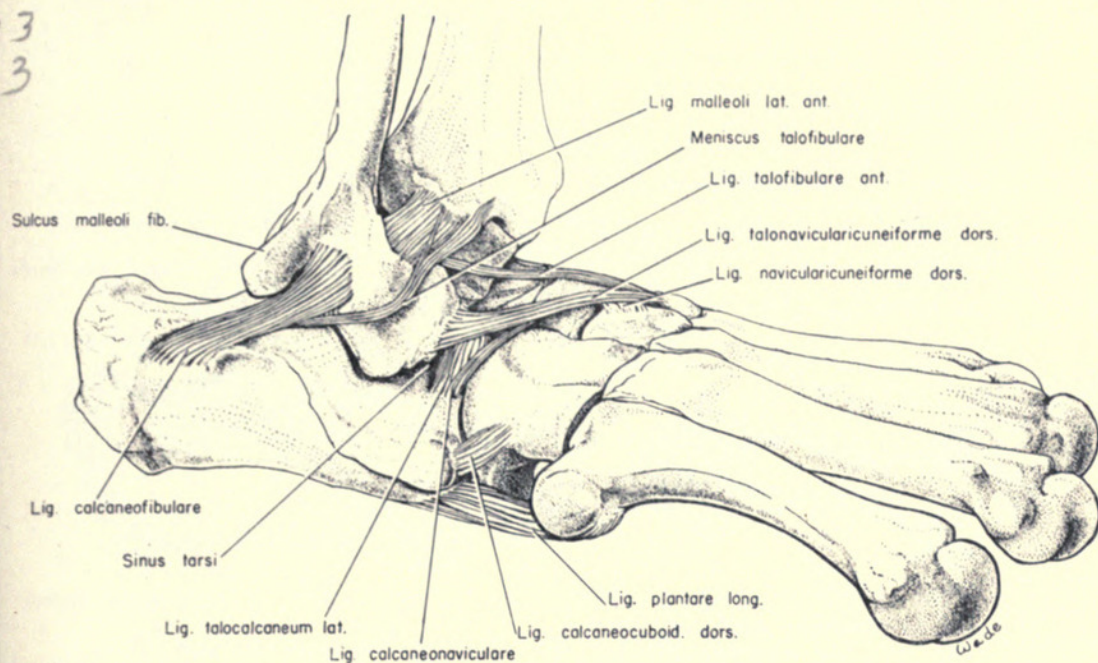


FIG. 12. Ligaments of right tarsus of *Tremarctos ornatus*, medial view.

ing. The shorter anterior and posterior talotibial ligaments, however, are present and are very similar to the corresponding structures in man.

The *posterior talotibial ligament* (fig. 13) is a band of fibers arising from the distal surface of the medial malleolus of the tibia, immediately anterior to the malleolar groove. The fibers pass downward and slightly backward, to insert into the medial surface of the body of the astragalus.

The *anterior talotibial ligament* (fig. 13) arises from the anterior margin of the medial malleolus, directly laterad of the origin of the posterior talotibial ligament, and passes forward and downward to the dorsal surface of the neck of the astragalus, below the anterior part of the medial malleolar surface.

A well-developed interarticular meniscus, the *talofibular meniscus* (new name), is situated between the lateral malleolus of the fibula and the lateral malleolar surface of the astragalus (fig. 12). The meniscus is a narrow crescent-shaped structure, 14 mm. long by 3 mm. wide. It is wedge-shaped in cross section, the thick outer edge measuring about 1 mm. The lateral end of the cartilage is held in place by a tract of fibers that emerges from beneath the calcaneofibular ligament and apparently represents a differentiation from that ligament; the medial end is held by a tract of fibers lying superficial to the anterior lateral malleolar ligament and apparently representing a differentiation from that ligament.

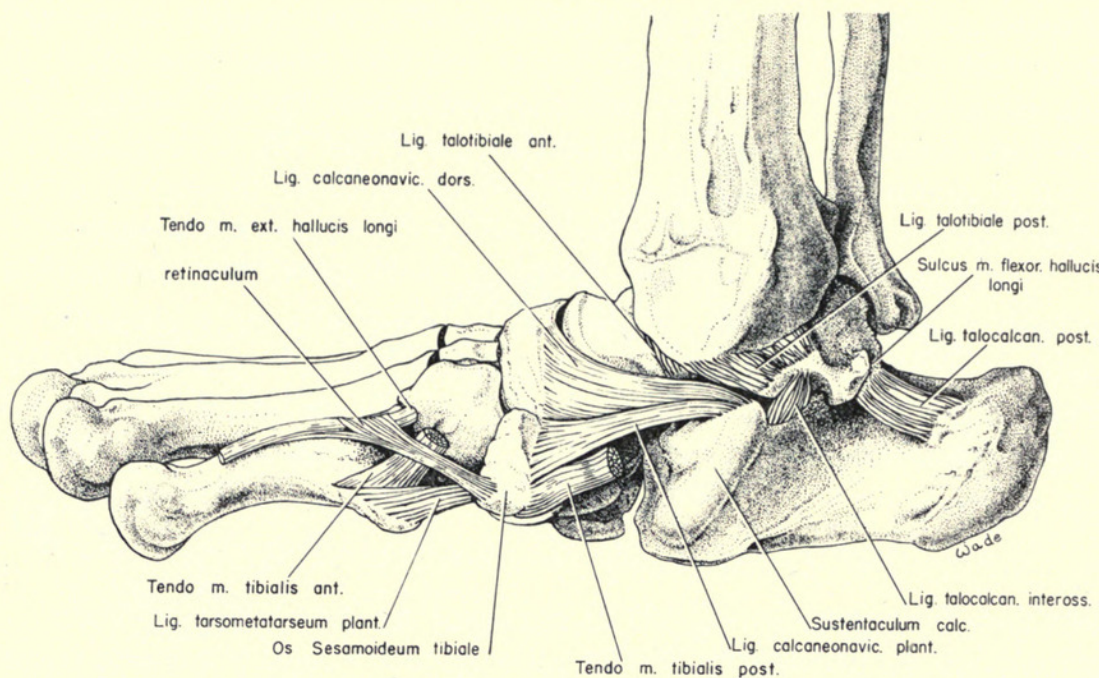


FIG. 13. Ligaments of right tarsus of *Tremarctos ornatus*, lateral view.

The presence of this interarticular meniscus implies lateral thrust of the astragalus against the fibula. Such thrust would be developed if the foot were employed in a position of strong inversion, as it is in climbing.

INTERTARSAL ARTICULATIONS

TALOCALCANEAL LIGAMENTS

The talocalcaneal joint is the key to all tarsal movements except those in the sagittal plane (extension and flexion). The astragalus and calcaneus are bound together by five short ligaments, as in man, and their arrangement and relations are similar to those in man. The functioning of these ligaments may be compared roughly with the cruciate ligaments of the knee. In the bear, however, the talocalcaneal group is dominated by two of these bands, the lateral and medial talocalcaneal ligaments, which greatly exceed the others in bulk. The medial in particular differs from the corresponding ligament in man.

The *posterior talocalcaneal ligament* (fig. 13) is a broad flat band forming the lateral wall of the groove for the flexor hallucis longus tendon. The short fibers attach at one end to the astragalus along the lateral edge of the groove, run backward and slightly downward, and attach to the medial surface of the neck of the calcaneus a short

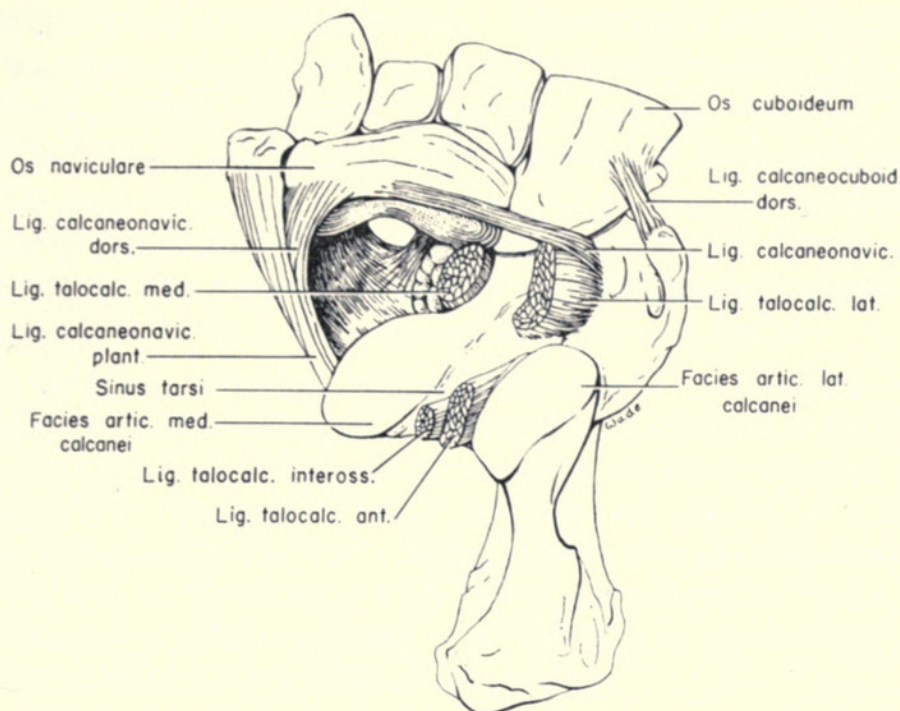


FIG. 14. Ligaments of right tarsus of *Tremarctos ornatus*, dorsal view, after removal of astragalus.

distance behind the lateral facet; a slight scar on the bone marks the site of attachment.

The *anterior talocalcaneal ligament* (fig. 14) is situated, as in man, in the sinus tarsi posterior to the interosseous ligament. It attaches at one end to the calcaneus immediately anterior to the lateral facet, and at the other to the astragalus along the anteromedial border of the lateral facet.

The *medial talocalcaneal ligament* (figs. 14, 15) is a very heavy rope-like tract of fibers. It is attached at one end to the inferior surface of the astragalus, in the fovea-like depression between the navicular articular surface and the medial facet, and at the other end to the medial surface of the calcaneus immediately in front of the sustentaculum. Thus the fiber direction is diagonally downward and outward.

The deep fovea-like depression on the astragalus, reminiscent of the fovea on the head of the femur, is wanting in man and other primates. In man its site is occupied by the articular surface for the plantar calcaneonavicular ligament (this articulation is wanting in the bear), and in man the medial ligament is shifted back to the posterior process at the rear of the astragalus. The fovea is present in other carnivores, in the creodont *Claenodon*, and at least in *Eri-*

naceus among the insectivores. Thus it appears that the attachment site in man (and presumably in other primates) is a secondary one, as the ligament has been displaced from its original site by the development of an articulation with the plantar calcaneonavicular ligament.

The *lateral talocalcaneal ligament* (figs. 14, 15) is likewise a very heavy tract of short fibers. It attaches at one end to the lateral

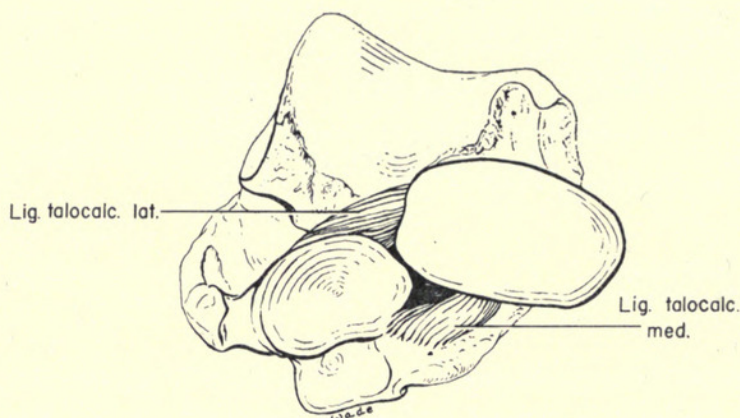


FIG. 15. Anterior view of right astragalus and calcaneus of *Tremarctos ornatus*, showing relations of lateral and medial talocalcaneal ligaments.

surface of the neck of the astragalus, and at the other to the superior surface of the calcaneus, in front of the lateral facet; a conspicuous scar marks the calcaneal attachment site. Fiber direction, as for the medial ligament, is diagonally downward and outward.

The lateral and medial ligaments embrace the long axis of the medial articular facets between them, thus severely restricting antero-posterior gliding movements in this part of the joint. They actually embrace a shifting vertical axis for the lower tarsal joint, restricting movements between the astragalus and calcaneus almost entirely to rotation around this axis. The result is that major excursion in the lower tarsal joint is between the two lateral facets, which are longer than the medial facets to accommodate this movement. Because of the arching of the lateral facets, rotatory movements in the lower tarsal joint are translated into eversion-inversion movements of the foot.

The *interosseous ligament* (fig. 14) is similar to the corresponding ligament of man. It lies in the sinus tarsi and consists of a long tract of short fibers extending between the astragalar and calcaneal grooves.

DORSAL TARSAL LIGAMENTS

A *dorsal talonaviculocuneiform ligament* (fig. 12) represents the dorsal talonavicular ligament of human anatomy. In the bear it is a flat band running diagonally across the dorsal surface of the foot, from the anterior surface of the body of the astragalus lateral to the neck, to the dorsal surface of the second cuneiform. The ligament is attached to the superior surface of the navicular as it passes over that bone, but its main attachment is to the cuneiform.

The bifurcate ligament of man is represented in the bear only by the superior (calcaneonavicular) part; the inferior (calcaneocuboid) part is wanting. The pars calcaneocuboidea is often wanting in man (Braus, 1929). The *calcaneonavicular ligament* (fig. 14) is a thin flat band running across the dorsum of the foot, from a point just above the distal end of the trochlear process of the calcaneus to the dorso-lateral corner of the navicular. Its medial end passes deep to the anterior talonavicular ligament.

The *dorsal calcaneocuboid ligament* (fig. 14) is a short flat band extending anterolaterally from the anteromedial angle of the coracoid process of the calcaneus to the superior surface of the cuboid near its posteromedial angle.

The *dorsal cuboideonavicular ligament* is a short band extending transversely between the lateral border of the navicular and the adjacent border of the cuboid on the dorsum of the foot.

The *dorsal naviculocuneiform ligaments* are represented by three isolated short bands extending between the anterior border of the dorsum of the navicular and the superior surfaces of the cuneiforms, one ligament passing to each of the three bones. The broadest ligament is associated with the third cuneiform.

PLANTAR TARSAL LIGAMENTS

The ligaments on the plantar surface differ considerably from those in man, not only in detail but also in basic pattern. Fibrocartilaginous sesamoid cartilages are more extensively developed than in man. The *navicular fibrocartilage* of human anatomy is represented by a large nodule situated beneath the medial end of the navicular, the first cuneiform, and the tibial sesamoid. It is associated with the insertion of the tendon of the posterior tibial muscle and the ventral fibers of the plantar calcaneonavicular ligament. There is also a group of *metatarsal fibrocartilages* beneath the proximal ends of metatarsals 2-4, which are associated with the attachments of the

long plantar, the medial plantar, and the plantar tarsometatarsal ligaments.

The *long plantar ligament* (figs. 12, 16) is the largest tarsal ligament. It is composed of two subequal parts, a lateral part passing over two joints and a compound medial part that extends over one joint at a time. The two parts are inseparable proximally, arising as a unit from the prominent anterior tubercle on the inferior surface of the calcaneus near the cuboid articulation. The lateral part passes over the ventral tuberosity of the cuboid without attaching to the bone, and inserts into the ventral tuberosity at the base of the fifth metatarsal.

The medial part of the long plantar ligament is interrupted by the ventral tuberosity of the cuboid, which divides it into proximal and distal parts. The proximal fibers, arising from the anterior tubercle of the calcaneus, insert into the proximal surface of the cuboid tuberosity. The distal fibers arise from the distal border of the cuboid tuberosity and insert into the metatarsal fibrocartilage underlying the base of the fourth metatarsal.

The *medial plantar ligament* (new name) is not represented in man. It lies parallel to and immediately mesad of the long plantar ligament, separated from the latter by an interval (fig. 16). Like the long plantar ligament, it is composed of a long and a short element. These have a common proximal origin from the antero-inferior border of the calcaneus directly above the groove for the flexor hallucis longus. The long lateral part passes over the tuberosity of the navicular without attaching to the bone, and inserts into the metatarsal fibrocartilage beneath the base of metatarsal 3. The short medial part attaches to the proximal and inferior surfaces of the tuberosity of the navicular.

The *plantar calcaneocuboid ligament* (short plantar ligament) is completely covered by the long plantar ligament. It is a short band attached to the anterior surface of the calcaneus between the anterior tubercle and the cuboid articular surface, and passes straight forward to attach to the inferior surface of the cuboid between the tubercle and the calcaneal articular surface.

The *plantar calcaneonavicular ligament* (figs. 13, 14, 16) is a broad thick plate arising from the whole anterior border of the sustentaculum and inserting into the medial part of the inferior surface of the navicular, the proximal surface of the tibial sesamoid, and the navicular fibrocartilage. Dorsomedially it is blended with the inferior edge of the dorsal calcaneonavicular ligament. The general fiber

direction is antero-posterior. The ligament bridges the medial part of the notch between the sustentaculum and the navicular; the lateral part of this notch is filled with fat, connective tissue, and the medial talocalcaneal ligament (fig. 14). The inner surface is cupped to receive the head of the astragalus. Thus the ligament would appear to form a functional part of the socket in which the head of the astragalus articulates, as it does in man. In the bear there is no articular surface on the opposing area of the astragalus, however, and it is therefore evident that the ligament does not help support the down thrust of the astragalus head as it does in man. A large nodule of fibrocartilage, the *navicular fibrocartilage* of human anatomy, is embedded in the ligament between the medial ends of the

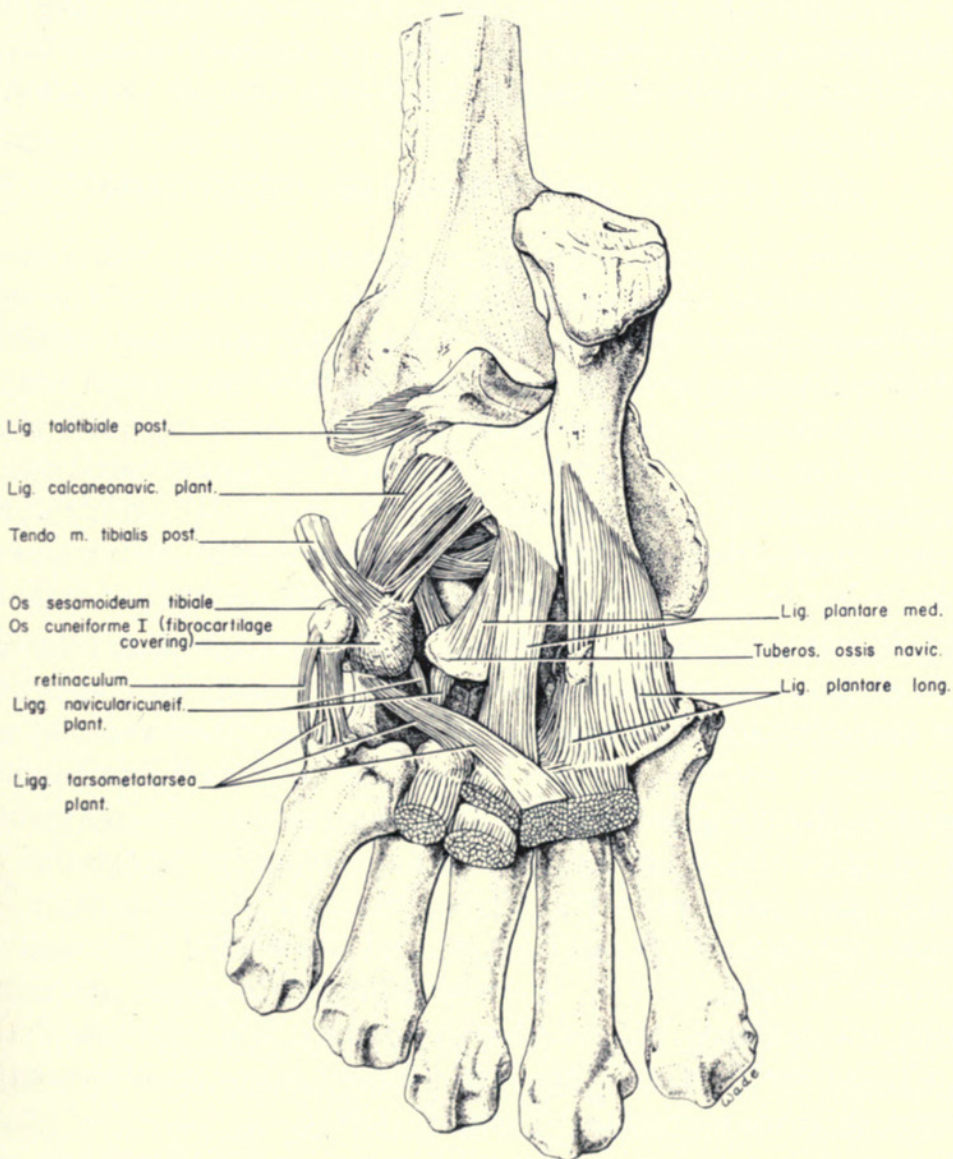


FIG. 16. Ligaments of right tarsus of *Tremarctos ornatus*, plantar view.

sustentaculum and the navicular; distally it is embraced between the tuberosity of the navicular and the tibial sesamoid. The medial face of the ligament is grooved for the posterior tibial tendon, which does not pass beneath the ligament and provide additional support for the astragalar head as it does in man.

The *plantar cuboideonavicular ligament* is a short transverse band running from the lateral surface of the navicular tubercle to the medial surface of the cuboid tubercle. It lies deep to the plantar calcaneonavicular ligament.

The *plantar navicularicuneiform ligaments* (fig. 16) are represented by two distinct sets of short bands. One extends anteriorly and dorsally from the anterior border of the navicular tuberosity to the inferior surfaces of the second and third cuneiforms. The other extends medially from the medial border of the navicular tuberosity to the inferior surface of the first cuneiform near its posterior end.

RELATIONS OF THE TIBIAL SESAMOID

The bears, like most pentadactyl mammals, have an accessory bone, the so-called tibial sesamoid, on the medial side of the second row of tarsals (figs. 13, 16). In *Tremarctos* this bone articulates about equally with the navicular and the first cuneiform. This is not a true diarthrosis; there is no articular cavity and the contact surfaces of the bones are not covered with articular cartilage. Instead, the sesamoid is tightly bound to the navicular and first cuneiform by tough fibrocartilage, which is particularly heavy at the periphery but is also present over the contact surfaces.

To the tibial sesamoid are attached certain tendons and ligaments that in man attach elsewhere. It serves primarily as the principal site of insertion for the tendon of the posterior tibial muscle, which in man inserts chiefly into the tubercle of the navicular bone.¹ In *Tremarctos* the tibial sesamoid is held in place by two ligaments, in addition to the fibrocartilage that binds it directly to the navicular and first cuneiform: the lateral fibers of the plantar calcaneonavicular ligament attach to its proximal face, and the medialmost element of the plantar tarsometatarsal ligament to its distal face. A retinaculum for the tendons of the tibialis anterior and extensor hallucis longus attaches to its external face. These relations are essentially the same in other mammals (Carlsson, 1891).

¹ Whether or not the sesamoid often found in this tendon in man is homologous with the tibial sesamoid of quadrupeds seems to me a sterile argument.

The functional significance of the tibial sesamoid, and of its counterpart in the forefoot, the radial sesamoid, is not clear. The absence of an articular cavity shows that the bone is essentially immobile. Its primary purpose would therefore seem to be to broaden the tarsus, although the advantage of broadening the tarsal complex in this peculiar way is not evident.

TARSAL MOVEMENTS

Attempts to localize and verify movements of the tarsal bones by means of superimposed X-ray photographs are not entirely successful because of the small size of the bones and the complexity of the movements. Tracings of the photographs (figs. 17, 18) do verify deductions from the dissection and from manipulation of tarsal bones. Really accurate analysis of these movements in the bear would require the use of targets mounted on the ends of long radii inserted into the bones, a technic developed by Close and Inman (1953) in their work on the human tarsus.

DISCUSSION

The tarsus of the bear is a relatively unspecialized mammalian structure, the bones differing little from those of generalized ferungulates of Paleocene age. The only plantigrade mammal whose tarsal ligaments are known is man, and consequently it is with man that the ligaments of the bear must be compared. To find an ancestor common to the Carnivora and the Primates it is necessary to go back at least 80 million years, into the Cretaceous.

The general pattern of the tarsal ligaments is very similar between *Tremarctos* and man. There are several differences, however, and these are intimately related to differences in the mechanics of the tarsus. They are:

1. In the talocrural (upper tarsal) joint two ligaments found in man are absent in the bear: the calcaneotibial and tibionavicular. In man these both lie on the medial side of the joint, and both pass over two joints. Thus they strengthen the ankle assembly, but they do so at the expense of flexibility.

2. In the talocalcaneal (lower tarsal) joint of the bear the powerful lateral and medial talocalcaneal ligaments are as important as the articular surfaces on the bones in determining the nature of joint movements. By fixing a slightly shifting center of rotation just anterior to the medial facets, these ligaments permit rotatory move-

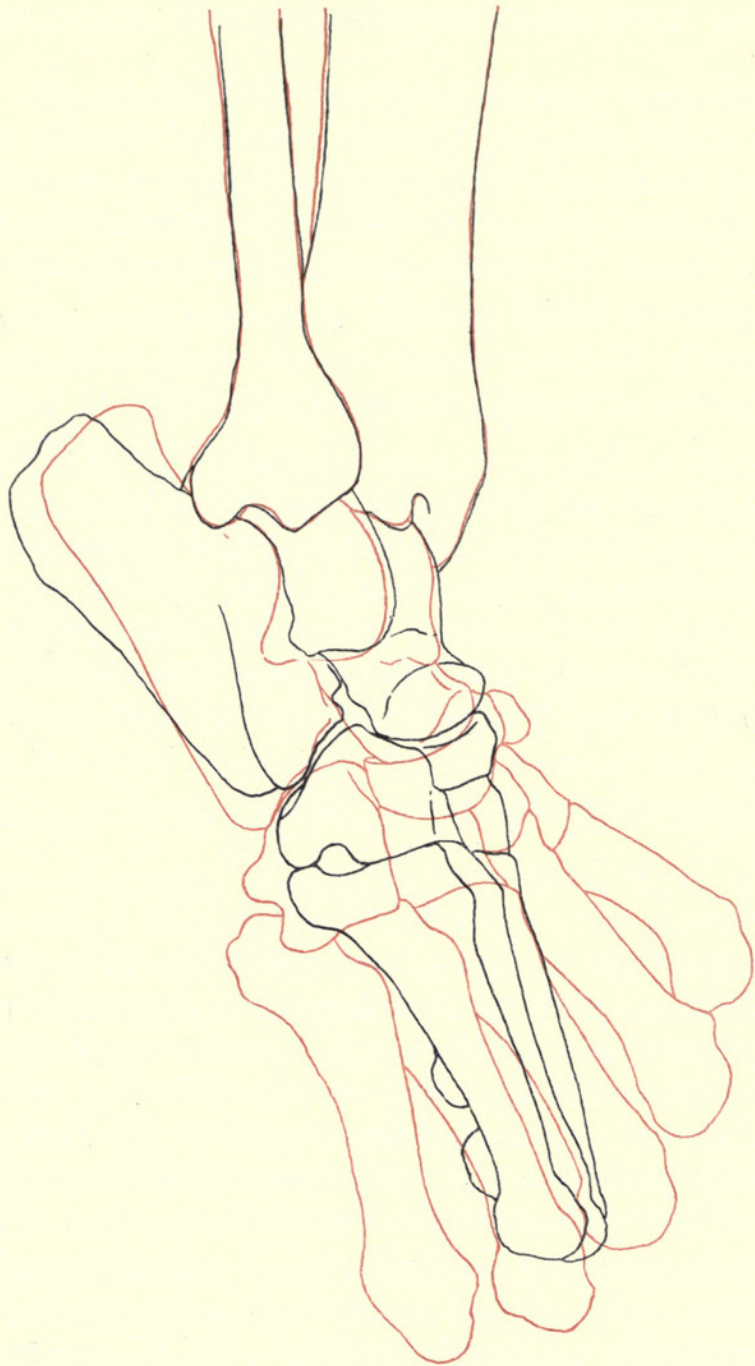


FIG. 17. Tracings from X-ray photos of right tarsus and pes of *Tremarctos ornatus* in positions of inversion and eversion. Embalmed specimen; muscles removed, ligaments intact; tibia clamped in vise and foot manipulated from distal end. The black lines show the foot in eversion, the red lines in inversion, with the outlines of the tibia superimposed. In the *upper tarsal joint* there is very slight rotation of the astragalus around the long axis of the tibia. In the *lower tarsal joint* the maximum permissible rotation of the calcaneus takes place around the astragalus. Rotation is around a vertical axis passing obliquely downward and outward through the trochlea of the astragalus, then through the calcaneus anterior to the medial facet. The site of this axis is determined largely by the lateral and medial talocalcaneal ligaments. In the *transverse tarsal joint* the navicular-cuboid unit rotates around a longitudinal axis passing proximo-distally through the interspace between the two bones. The range of inversion-eversion movements of the foot results from additive movements of both the lower and transverse tarsal joints.

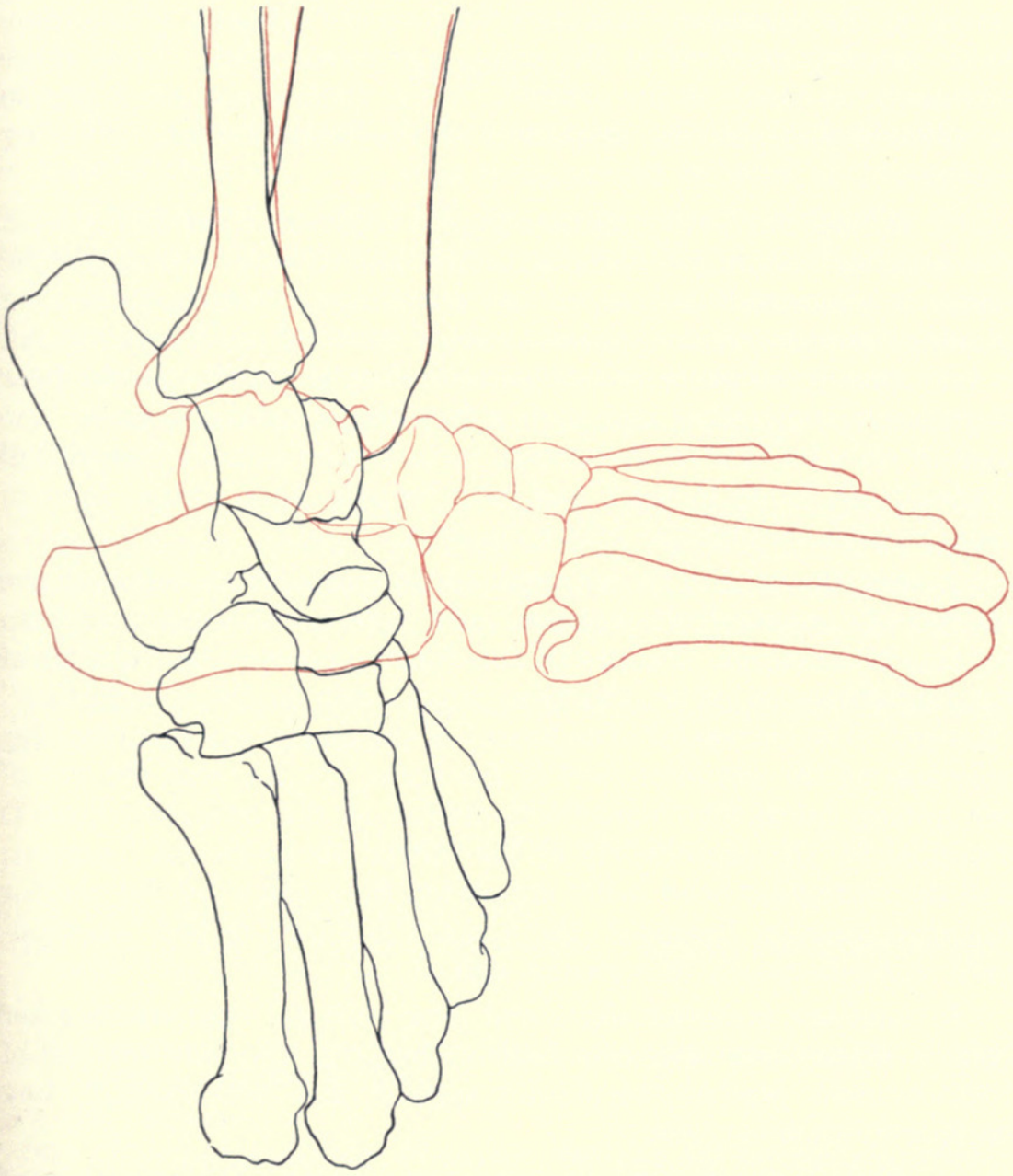


FIG. 18. Tracings from X-ray photos of right tarsus and pes of *Tremarctos ornatus* in positions of extension and flexion. Data as for figure 17. Movement is exclusively in the upper tarsal joint. Extension is accompanied by a slight displacement forward and upward of the fibula with relation to the tibia.

ments of the astragalar head—movements vital to eversion-inversion movements of the foot. They do not, however, allow the head to be displaced significantly from its position vis-à-vis the cuboid articulation on the calcaneus—a feature vital to the integrity of the four-bone complex involved in the transverse tarsal joint. Thus these ligaments, as much as the articular facets themselves, are a key to an understanding of the mechanics of the bear's tarsus. Nothing comparable is found in the tarsus of man.

3. In man the major plantar complex is concerned primarily with the structural stability of the longitudinal and transverse arches of the foot. It is long and narrow, concentrated along the axis of the long plantar ligament; the axis passes through the third metatarsal (which is very nearly the plane of balance of the human foot). In the bear there is no longitudinal arch and no functional transverse arch. The plantar complex is short and broad, including a ligament (the medial plantar) not found in man, and with its axis more laterad than in man, passing through the fifth metatarsal.

In man the head of the astragalus is supported from below by the plantar calcaneonavicular ligament, and bears a special articular area for this articulation. Failure of this ligament results in "a kind of flat-footedness, in which the talus sinks down to the sole surface" (Braus). The astragalar attachment of the medial talocalcaneal ligament is on the posterior part of the bone. In the bear the site of the human calcaneonavicular articulation on the astragalar head is occupied by the attachment of the medial talocalcaneal ligament, and the astragalar head is not supported from below by the plantar calcaneonavicular ligament; the ligamentary part of the "acetabulum" consists mostly of a medial wall.

In man the posterior tibial and long peroneal tendons together form a stirrup that supports both arches. In the bear neither of these tendons reaches the plantar surface, and consequently they provide no such support.

4. The tibial sesamoid is a primitive mammalian structure of uncertain functional significance. Its absence in man represents a departure from the primitive condition.

In general the tarsus of the bear is a far more flexible structure than its human counterpart. Even the upper tarsal joint (between tibia and astragalus) appears to be less rigidly restricted to hinge movement than in man. Range of movement in the lower tarsal joint (between astragalus and calcaneus) is notably greater than in man, and this is likewise true of the transverse tarsal joint. As a

supporting structure, on the other hand, it is more poorly designed for distributing stresses and strains, and thus for enhancing the stability of the limb as a whole.

SUMMARY

1. The tarsal ligaments of the spectacled bear are basically similar to those of man.
2. Three ligaments found in man—the calcaneotibial, the tibio-navicular, and the calcaneocuboid—are wanting in the bear.
3. One ligament found in the bear—the medial plantar—is wanting in man. This ligament is associated with a broad short plantar complex that contrasts with the narrow long complex of man.
4. In the bear an interarticular meniscus is situated in the talo-fibular joint.
5. In the bear the medial and lateral talocalcaneal ligaments are extremely heavy, embrace the head of the astragalus, and are the key to movements in the lower tarsal joint. In man the medial ligament has been displaced backward from its original attachment site on the head of the astragalus.
6. The tarsus of the bear is a more flexible but less stable structure than is the tarsus of man.

REFERENCES

- BAUM, HERMANN, and ZIETZSCHMANN, OTTO
1936. *Handbuch der Anatomie des Hundes*. I. Skelett- und Muskelsystems. Berlin: Parey; viii, 242 pp., 180 figs.
- BRAUS, HERMANN
1929. *Anatomie des Menschen*. Ed. 2. 1, Bewegungsapparat. Berlin: Springer; xi, 822 pp., 387 figs.
- CARLSSON, ALBERTINA
1891. Untersuchungen über die weichen Teile der s.g. überzähligen Strahlen an Hand und Fuss. *Bihang K. Svenska Vet.-Akad. Handl.*, 16, Afd. 4, no. 8, pp. 1-40, 4 pls.
- CLOSE, J. R., and INMAN, V. T.
1953. The action of the subtalar joint. *Prosthetic Devices Res. Proj.*, Univ. Calif., ser. 2, Issue 24, 7 pp., 12 figs.
- MORTON, D. J.
1935. *The human foot; its evolution, physiology and functional disorder*. New York: Columbia Univ. Press; xiii, 244 pp., 100 figs.
- REIGHARD, JACOB, and JENNINGS, H. S.
1901. *Anatomy of the cat*. New York: Holt; xx, 498 pp., 173 figs.



Davis, D. Dwight. 1958. "Tarsal ligaments of the spectacled bear *Tremarctos ornatus*." *Fieldiana* 39, 91–105.

View This Item Online: <https://www.biodiversitylibrary.org/item/21514>

Permalink: <https://www.biodiversitylibrary.org/partpdf/15605>

Holding Institution

University Library, University of Illinois Urbana Champaign

Sponsored by

University of Illinois Urbana-Champaign

Copyright & Reuse

Copyright Status: In copyright. Digitized with the permission of the rights holder.

Rights Holder: Field Museum of Natural History

License: <http://creativecommons.org/licenses/by-nc-sa/3.0/>

Rights: <https://biodiversitylibrary.org/permissions>

This document was created from content at the **Biodiversity Heritage Library**, the world's largest open access digital library for biodiversity literature and archives. Visit BHL at <https://www.biodiversitylibrary.org>.