

OSTEOLOGICAL AND OTHER NOTES ON THE MONKEY-EATING EAGLE OF THE PHILIPPINES, *PITHECOPHAGA JEFFERYI* GRANT

By R. W. SHUFELDT

Major, Medical Corps, United States Army, Washington, D. C.

ELEVEN PLATES

Some time during the latter part of March, 1918, the captive specimen of the monkey-eating eagle of the Philippines (*Pithecophaga jefferyi* Grant), of the botanic garden of Manila, died, and the dead bird was immediately sent to the Bureau of Science, Manila. In his letter to me of April 1, 1918, Mr. McGregor stated that from this material he—

got a good skin—the first! in our collection, although we have a poor mounted specimen. The bones are being cleaned. They will lack the feet, the skull, and the ends of the wings. However, I shall supply a head and a foot from another specimen, so that the thing is nearly complete. The description of this should make a good paper, especially if you can lay hands on bones of the harpy eagle and other related genera.

All this material was received by me in the summer of 1918; and it was in excellent condition. I prepared and photographed the specimens myself. Later, the division of birds of the United States National Museum kindly loaned me certain skeletons, with which I intended to compare the bones of *Pithecophaga jefferyi*. These consisted of an imperfect skull of *Morphnus guianensis* (Daudin), adult (No. 18468); a complete skeleton of an adult *Thalassoaëtus pelagicus* (Pallas), collected by Paul L. Jouy in Korea (No. 18222); an *Aquila chrysaëtos canadensis* (Gmelin), female, adult, complete and disarticulated (No. 18802); a complete, disarticulated skeleton of *Gypaëtus barbatus* (Linnæus) (No. 17834); a complete skeleton, disarticulated, of *Haliaëtus leucocephalus* (Linnæus), adult (No. 19278); and, finally, an incomplete skeleton of the harpy eagle, *Thrasaëtos harpyja* (Linnæus), adult (No. 225806). The last-named specimen lacked the skull. This bird was, during life, for several years one of the ornaments of the bird collection of the National Zoölogical Park at Washington. The skull was probably left in the skin. Subsequently I endeavored to obtain a skull of this species from the

Academy of Natural Sciences of Philadelphia, but was unable to do so.

It is very much to be regretted that a skull of the harpy eagle is not at hand for comparison with that part of the skeleton of *Pithecophaga*. Probably there is not a cleaned skull of the harpy eagle in the United States—adult, subadult, or young. This is invariably the case with respect to any bird before a glut takes place in museums and private collections of birds; the skulls are left in the skins!

THE CRANIUM, MANDIBLE, AND ASSOCIATED BONES OF PITHECOPHAGA

It matters but little from what point of view we may regard the cranium of this great eagle, the fact will at once be appreciated that at least two of its characters are so pronounced and so characteristic of the species that to confuse this part of the skeleton with the cranium of any other known eagle would be quite out of the question. In the first place, the lacrymal bones and their accessory outer pieces are of great size, while a still more conspicuous character is to be seen in the size and form of the osseous superior mandible; this is powerfully hooked, with cultrate tomia. It is transversely compressed almost to the last degree, the transverse diameter at the base beneath being slightly less than 2.5 centimeters, while the vertical height at the same point measures nearly 4 centimeters. Measured mesially below, it has a length of about 5.02 centimeters. Either narial aperture is very large, and these openings do not communicate through and through; anteriorly either one merges into the general surface of the side of the beak, while posteriorly greater depth is present, and the surrounding margin is sharp and triangular in outline; the apex of the triangle is posterior and above (Plate I, fig. 1).

Turning to the large lacrymals mentioned above, their form and proportions are well shown in the illustration (Plate I, fig. 2), while the descending limb is portrayed on the same plate. As is the case with so many large raptorial birds, these lacrymal bones, in adult life, do not fuse with the frontal and nasal upon either side nor with the large, subtriangular accessory piece supported at the outer end of each (fig. 2). The descending orbital limb of a lacrymal is constricted superiorly, anteroposteriorly flattened below, while it is broader and concaved in front from above downward. This part of a lacrymal does not come in contact either with the small, thin pars plana within or with the zygoma below.

Passing again to the dorsal aspect of the cranium, it will be observed, in the craniofacial region, that a considerable depression or concavity is present in the median area; posterior to this the frontal region is broad and flat, with the superior orbital margin cultrate. As in most eagles, the broad cranial vault is rounded and smooth, being marked only by the wonderfully fine, rambling, anastomosing lines that in life harbor the vessels of that region. I find these very well marked in the cranium of a white-headed eagle (*Haliaetus leucocephalus*) (Plate II, fig. 1) where, likewise, the depression in the craniofrontal region is pronounced. Throughout the diurnal Raptores, this character varies to some degree for the species. It is fairly well marked in the cranium of *Morphnus guianensis*; and several of the cranial characters thus far described in the cranium in *Pithecophaga* are more or less in agreement with the corresponding ones in this bird (Plate II, fig. 3). This in no way takes size into consideration, for *Morphnus* is not more than half the size of the monkey-eating eagle while, in a way, it does refer to the marked craniofacial depression, the lacrymals, and the general form of the osseous superior mandible. No other parts whatever have been seen or examined by me, and even the remainder of this cranium is very imperfect. When the material was selected for me at the United States National Museum, in addition to those designated by myself, this imperfect cranium of *Morphnus* was included.

In *Gypaëtus barbatus* a lacrymal does not support a free distal piece as in some eagles, while the superior outstanding portion is to a degree elongate and to some extent twisted upon itself. This bird has considerably more eagle in its skull, and in the rest of its skeleton for that matter, than it has vulture. However this may be, it has no special affinity with *Pithecophaga*, in so far as its skeleton would seem to indicate; and it is very much to be doubted that any of the rest of its morphology would point to any such relationship. Nothing would be gained, therefore, by a comparison of the skeletal characters of these two birds, beyond a demonstration of the fact that they possess no near relationship; and this much is evident to any expert avian osteologist at a glance. This in no way applies, however, to such a form as the big eagle of Korea, *Thalassoaëtus pelagicus*, a complete disarticulated skeleton of which (No. 18222, United States National Museum) I have before me. Paul L. Jouy collected it in that country many years ago. In its cranium it exhibits all the aquiline characters of an average eagle, including

the accessor pieces on the lacrymals. Upon summing up its cranial characters, however, it is very evident that it is not as nearly related to *Pithecophaga* as is the golden eagle (No. 18802, United States National Museum) (Plate II, fig. 2).

All eagles thus far examined by me possess, upon lateral aspect of the cranium, a deep, rounded, separated crotaphyte fossa; a large, squarish postfrontal process; and a squamosal projection. This does not show very well in fig. 1 of the present memoir, due to faulty lighting of the skull; nor do we, in the same figure, gain any idea of the enormous capacity and depth of the orbit that exists in the cranium of our subject. Indeed, it measures as much as 3 centimeters from the lower edge of the postfrontal process to the edge of the subcircular vacuity in the interorbital septum in *Pithecophaga*. This vacuity is also to be seen in the cranium of the golden eagle, but not in the white-headed species of North America. The anterior wall of the brain case in our subject is markedly concaved on its anterior aspect, and nonperforated beyond the usual foramina for vessels and nerves, all of which latter are comparatively small and individualized. So far as I have examined their crania, this is more or less true of all eagles.

As will be observed in Plate I, fig. 1, the quadratojugal bar in this monkey-eating eagle is quite straight, and of nearly uniform caliber from one end to the other. It is so in all true aquiline species, and in some the maxillojugal suture persists throughout the life of the individual.

A quadrate is a big, stout bone, with a well-developed orbital process, and a broad, smooth surface on its outer aspect. A broad, longitudinal valley lies between the two thoroughly separated articular facets that occur on its lower mandibular portion. It presents two heads for articulation with the skull, and they are separated by a wide, smooth notch. Nearly all parts of this cranium are pneumatic, and to this the quadrate forms no exception.

Either pterygoid bone is small, straight, short, and slender. When duly articulated, it does not come in contact with its fellow of the opposite side. In the golden eagle the outer margin of a pterygoid is very sharp and thin. This aspect in the white-headed eagle is longitudinally grooved, and the posterior extremity of the bone possesses an upturned process for additional articulation with the quadrate.

All true eagles possess a vomer, which is a long, thin plate

of bone compressed from side to side, with a finely pointed, free anterior apex; and, further, it is ununited posteriorly with the palatines.

Pithecophaga possesses large, spongy maxillopalatines that fill up a good part of the rhinal chamber, being carried far to the front above the prepalatines, where they appear to merge to a slight degree. They are separated for their entire length in *Aquila*, but extensively fuse in *Haliaeetus leucocephalus*, where they form a nearly solid roof in the mouth in connection with prepalatines and maxillaries.

Pithecophaga has a very solid bony nasal septum, as has the white-headed eagle; while in the golden eagle a good-sized vacuity may occur at the posterior superior angle.

The hinder part of a palatine in any true eagle has the postero-external angle rounded off, the bone in this locality being rather broad, with its inner margin produced and turned down, and its outer one to some degree thickened. In this part of their extent the palatines are in contact with each other, clasping the vomer between them anteriorly and the sphenoidal rostrum above.

The basipterygoidal processes are entirely absent in the skulls of all the eagles at hand at this writing, save in the case of the golden eagles, where they are represented by small triangular prickles, flattened from above downward. A lip of bone usually underlaps the entrances to the carotid arteries.

Pithecophaga—and other species of eagles depart but little from it—presents a triangular area for the basitemporal space of the cranium, with a marked depression just anterior to the hemispherical occipital condyle. The foramen magnum is large and nearly circular in outline. A superoccipital prominence is fairly well developed in all these eagles, including the Korean species.

Although the "occipital area" is well defined, the ridge that exists to mark its limitations is not much raised. This is also true of the "crotaphyte fossæ," which are extremely shallow, subcircular in outline, and widely separated posteriorly. At the side of the cranium the crotaphyte fossa extends over onto the external surface of the postfrontal apophysis.

The cranial capacity is only of moderate proportions, when taken in connection with the balance of that part of the skull; and this is especially true of the cranium of *Pithecophaga*.

Laterally, the osseous aural apertures are much exposed; in life, however, the soft structures of the internal ear are more or

less protected by the conformation of the quadrate when that element, upon either side, is placed in articulation.

There are some twelve to fifteen sclerotal plates to the circlet in either eyeball; the smaller ones are situated anteriorly and the larger ones behind (Plate III, fig. 9). Each platelet is an irregular quadrilateral in outline, the whole arrangement being fitted to the requirements of the form of the external moiety of the globe, assisting very materially in protecting it from certain injuries, and maintaining the sphericity of the organ. Additional strength is afforded through the generous overlapping of the plates.

We find the characters presented on the part of the mandible among the eagles pretty much the same, and it is V-shaped in all of the species at hand. In the long-faced species the V is more elongate, and the angle formed by the rami more acute. The bone is more or less pneumatic, which is also true of the cranium as a whole. In *Pithecophaga* a side of the mandible has a length of 9.7 centimeters, and the symphysis 2.5 centimeters, the latter being concave transversely above and correspondingly convex on its ventral aspect. All the elements are very solidly fused together, with the superior and inferior borders rounded. There are no perforating vacuities anywhere, the entire bone being very strong and smooth. A low coracoid process is present on either side, and from either of them the superior border slopes rather abruptly downward to the articular enlargement of the same side (Plate I, fig. 1; Plate III, fig. 4). Posteriorly, an articular extremity is considerably compressed from above downward, being truncate posteriorly. Its mesial, inturned process is somewhat elongate and well developed, with the usual pneumatic foramina near its apex superiorly. These processes are directed upward and inward, the apex in either case being blunt. Each presents two surfaces ventrally, and these are smooth. One surface is continuous with that of the jaw, the other pertaining to the underside of the inturned process.

Superiorly either one of these articular ends is concaved centrally, and that surface does not come in contact with the quadrate of the same side in articulation. Upon either side of this concavity, however, internally and externally situated, there is to be noted a conspicuous articular facet for articulation with the corresponding ones on the quadrate of the same side.

In many publications, here and abroad, I have described the skeletons of various species of eagles, falcons, hawks, and their

near congeners, both fossil and existing forms, and it may be said that we meet with few marked differences in any of them with respect to the characters presented on the part of the hyoidean arches, or skeleton of the lingual apparatus (Plate III, fig. 10).

The anterior soft part of the glossohyal is long and narrow, being covered for its anterior two-thirds with the usual horny sheath. Posterior to this, the glossohyal is narrow and bifurcated, articulating, as usual, with the basihyal posteriorly. This part is likewise thinly overlain with a horny sheath. All this part is very feebly developed, extremely elongate, and narrow.

Triangular in outline, the basihyal supports posteriorly an elongate urohyal, which is of small and nearly uniform caliber; it is tipped off with a very small bit of cartilage behind. This urohyal is perpendicular to the transverse line of the base of the basihyal, and in the right angle upon either side of the former articulates the head of a hypobranchial. Each hypobranchial is long and curved upward for its entire length. Both the anterior and the distal ends are somewhat enlarged, the posterior enlargements being continued in cartilage for a few millimeters, when, upon either side, its place is taken by a ceratobranchial. Either one of these is about 1.5 centimeters long, slender, and to some extent curved in line with the upcurved hypobranchial of the same side. Each ceratobranchial terminates behind in a fine, needle-pointed, cartilaginous tip.

Our white-headed eagle (*Halixetus leucocephalus*) possesses a hyoid very similar to this; but the angle made by the urohyal and the basihyal is an obtuse one instead of a right angle, as it is in *Pithecophaga*, and the cartilaginous part of the glossohyal is extremely short, while the broad, osseous part has the form of a capital letter H, with the sides converging toward each other from behind forward.

Eagles, in so far as I have examined them, possess a very simple form of larynx and trachea. The former presents the usual osseous elements, but they form no special articulations with each other, the contour of the structure being sustained in their membrane, with the aforesaid elements simply maintained in their several positions by it, and nowhere in contact with each other. All the tracheal rings—and they are very numerous—appear to be, to some extent, performed in cartilage (Plate III, figs. 6, 10). Each is of the usual ornithic type, the broader ones being above and below. There are upward of seventy of

them, the lower end of the tube not having more than half the caliber of the upper, where it makes a simple union with the larynx. Distally, the bronchial branches are small, and but half closed in, the mesial aspect of either being a thin, simple membrane stretched across. There is a single pessalus present.

THE SKELETON OF THE TRUNK

The vertebral column.—All the skeletons of eagles that I have examined possess fourteen vertebræ in the cervical region of the spine, between the cranium and the first true dorsal vertebra. Each of the last two cervicals—the thirteen and the fourteenth—supports a free pair of ribs. On the thirteenth the pair is rudimentary, to the extent that the body of the bone on either side is lacking to some considerable degree, while the articulation is perfect for the head and angle. With respect to the pair of ribs on the fourteenth cervical vertebra, it has a length of some 5 centimeters, terminating in a pointed, free extremity well above the sternum. As this is the case with respect to these last two vertebræ in *Pithecophaga*, *Thrasaëtos harpyja*, *Aquila*, and our white-headed eagle, it is probably what we will find in the skeleton of any true aquiline species, irrespective of the part of the world it inhabits. As a matter of fact, the vertebral column of this monkey-eating eagle of the Philippines is, character for character, almost the counterpart of that series of bones in the harpy eagle, and departs but very little from what we find in other species.

In our present subject the atlas lacks both neural and hæmal spines, while the articular cup for the occipital condyle is notched above. Laterally, there may be a notch or a foramen for the passage of the vertebral artery upon either side. Its neural arch is rather broad, and the facet for the centrum of the axis is quadrilateral in outline, the width being twice that of the vertical height. At the middle point below, it is pierced longitudinally by a minute foramen; a broad notch being found at the same place in the atlas of the white-headed eagle. In this species, too, similar notches allow, in life, the passage of the vertebral arteries to the cranial cavity. Similar ones, though larger, are to be seen in the axis of *Pithecophaga*, in which vertebra are developed a stumpy hæmal and a neural spine, as well as a more or less insignificant odontoid process.

The neural canal throughout the cervical series of vertebræ is cylindrical in form and quite uniform in caliber. From the third to the twelfth vertebra, inclusive, the lateral foramina for

the vertebral arteries are, in all instances, entire—that is, with respect to their osseous walls; on the other hand, the carotid canal is an open passage for the arteries of that name in the fifth to the ninth cervical vertebra, inclusive (Plate III, figs. 3, 5, 7, and 8).

All of these cervical vertebræ are very large and strong—indeed, quite massive in character. When present, the neural spine is situated just within the posterior margin of the bone; it is directed backward and upward in the third vertebra; is vertical and peglike in the next following one, with broader and triangular base in the next three (fifth to seventh inclusive), wherein it moves forward to the middle of the neural arch, the angle being situated anteriorly, and either side being directed backward and outward.

In the third cervical the prezygapophyses and postzygapophyses are joined by a plate of bone, in which appears, on either side, a small elliptical foramen; this foramen in the next following vertebra becomes an extensive subelliptical notch, being reduced to a minute spine on either side in the fifth vertebra.

Returning to the matter of the neural spines, we find that the broad, triangular form they assume—described in a previous paragraph—persists in the eighth to the twelfth vertebra, inclusive. Here they are more massive and occupy an extreme posterior position on the several remaining vertebræ of this series. On the twelfth the spine begins to assume the form of the neural spine as we find it in the leading dorsals, while in the thirteenth and the fourteenth not only are the neural spines in agreement with those processes in the thoracic vertebræ, but they present almost all the other characters of that series. In the midcervical series, the pleurapophyses are short and stumpy.

The rather massive prezygapophysial processes in the fifth cervical face directly upward; in the sixth they look inward and backward, and they maintain this position to include the ninth. In the rest of the series they face inward again. The “carotid canal” is present and open in the fourth to the eighth cervical, inclusive, being most nearly closed in the last one named.

Coming to the dorsal vertebræ (Plate IV), we find them very closely interlocked in articulation, with long, spinelike metapophyses on the last four of the five which occur in this section of the spinal column. The hæmal spines are stumpy and short, being entirely absent on the last two dorsals. The neural canal is cylindrical in form; the facets for each pair of ribs are entire

and are situated well back from the anterior limitation of the centrum on any particular vertebra; that is to say, there are no demifacets (Plate VI).

There are no epipleural appendages on either the last pair of the cervical ribs or the last pair of the pelvic ones (Plate IV); and, while of no great size on the first pair of dorsal ribs and the leading pair of pelvic ribs, they are conspicuously long and massive on the ribs of all pairs constituting the midseries. Any of these, in articulation, overlaps the body of the next rib behind; and all of these processes, at least in adult life, are very extensively and firmly coössified to the rib to which in any case they belong. With respect to direction, they all point upward and backward.

In the harpy eagle the basic portion of any one of these epipleural appendages is notably extensive, and occupies, in the case of the second pair to include the fifth, a large part of the posterior border of the rib—fully a third at least. There is a smaller pair of these apophyses on the last pair of pelvic ribs (Plate V).

All the ribs in *Pithecophaga*, save the cervical ones, articulate with the sternum by means of costal, or sternal, ribs; and there are no floating ones on the last pair as there are in the case of the harpy eagle (fig. 17). In our subject these sternal ribs increase in due proportion, in size and length, as we proceed from the first to the last pair; they are more or less massive, in keeping with the rest of the skeleton of this ponderous bird, and the last two pairs exhibit more or less upward curvature (Plate IV).

Our white-headed eagle has the last pair of pelvic ribs more or less feebly developed. The thoracic pair, upon one side or the other, may be more or less aborted with respect to its length and not descend to meet the usually well-developed corresponding pair of sternal ribs in this bird.

The pelvis and the caudal vertebræ.—When we come to examine and compare the pelves of various species of eagles from different parts of the world, we are struck by the marked similarity of form and of characters among them. This applies with special significance to the pelvis as we find it in our present subject and in the harpy eagle. Here the different characters are of the most trivial description possible—so much so, indeed, that a detailed account of the pelvis of an adult *Pithecophaga jefferyi* would answer admirably for the same bone of the skeleton in the harpy. Upon comparing Plates IV and V of the present memoir, it would appear that the disposition of

the hinder part of the pubic style was very different in the two birds; but this is by no means the case, for in the harpy those elements are held in their normal position, as in life, by a ligament stretching between their distal ends; while in *Pithecophaga*, when this ligament has been cut, it allows the pubic styles to spring away from each other and hang down as shown on Plate IV. Moreover, the point of view from which I photographed those two trunk skeletons was not quite the same, and this causes the reproduction of the rest of the bone to present slight differences, which do not really exist.

Viewed from above, it is to be noted that the ilia project considerably beyond the sacral crest; and on the upper surface of their anterior border there is a raised emargination which is produced backward and finally runs out as a bounding line to the postacetabular area of the superior surface of the sacrum upon either side. As the ilia pass the "sacral crest," their margins thoroughly coössify with it and in the same plane anteriorly—that is, up to the point where these bones begin to diverge and are raised above the general surface on this dorsal aspect of the bone. At the angle where this divergence commences, the sacrum and the ilia are completely fused, and every semblance of posterior openings of the "ilioneural canals" is completely obliterated. So, too, with the rather abruptly downward-sloping "postacetabular area;" here, likewise, every semblance of sutural traces—the intersacroiliac ones—has been absorbed; while the intervertebral foramina, so conspicuous in this area in the pelves of some birds, are reduced to mere little pits in the general surface of the bone (Plate VI).

Seen upon lateral aspect (Plate IV), the anterior two-thirds of bone—or all that part anterior to and above the acetabulum and antitrochanter—is supplied by the ilium of that side. Its surface is generally concaved and faces upward and outward. Anteriorly, its outer border is emarginated, and below this may be seen the forepart of the pelvic sacrum, the continuation of which, posteriorly, may also be observed through the large, circular acetabulum and immense ischiadic foramen; the former is entirely lacking in any osseous base, while the latter occupies fully one-half of the lateral area posterior to the rather large, subtriangular antitrochanter and elliptical obturator foramen. Posterior to this great ischiadic foramen, the lateral surface of the ischium is triangular in outline, concave above, convex below, and smooth throughout. The rounded posterior ischiac border is nearly straight and presents no semblance of any indent that might suggest the presence of an "ilioischiadic."

The pubic style closes the obturator foramen; and, after passing it along the lower margin of the ischium, it becomes much attenuated and terminates as a fine point in a line below the middle of the ischiadic foramen above it. A small interval is then present, when the bone begins again in a fine point, to increase gradually in size as it passes below the inferior ischiac border, to be produced posteriorly in a much thickened condition in the direction of its fellow of the opposite side.

Ventrally, the pelvis of this eagle presents many interesting features. As well as I am able to judge from the pelvis of an adult bird of this species, the sacrum would seem to contain fifteen vertebræ, or the same number as we find within the grasp of the iliac bones of the harpy's pelvis. The leading seven possess very large centra, and they have their lateral processes extending upward and outward, to coössify with the ventral surfaces of the ilia. Posterior to this arrangement, we arrive at the very deep pelvic basin, where the three vertebræ opposite the cotyloid rings fail to throw out lateral processes. These are followed by three others that have the lateral processes for their external moieties fused into a common plate of bone upon either side, which fuses outwardly with the inner surface of the pelvic wall. A row of three elliptical foramina is left upon either side of the centra here, and osseous trabeculæ are thrown up into the deep space above. Finally, the two terminal sacral vertebræ occupy a much lower plane than the preceding—that is, their transverse processes do—and these are thrown directly outward, to fuse distally with the inner wall of the ischium upon either side. Below them the surface—and it is an extensive one—on either hand is smooth, being furnished entirely by an ischium.

The conformation I have attempted to describe here gives rise to four fairly well-defined cavities, each imperfectly walled in by the surrounding parts of the pelvis as a whole. Through these cavities, mesially, passes the big, coössified pelvic "sacrum." The first cavity occupies the anterior half of the pelvis backward to a point where the vertebræ cease to send their lateral processes directly outward to the iliac walls upon either hand. Then follows the well-marked, deep cavity opposite the acetabulæ; posterior to this we define cavity number three, which lies between the big ischiadic foramina; and, finally, ventrad to the last two, there is the general concavity of the pelvic basin, having cavities two and three above it, and its lateral walls formed by the ischium, descending deeply upon either side.

The skeleton of the tail of this eagle is composed of eight free vertebræ, plus a large, quadrilateral pygostyle. The first three vertebræ are pneumatic, while the rest of this caudal series does not enjoy this condition. Passing to the harpy eagle, we find that the tail skeleton contains but seven free vertebræ and a pygostyle; the latter is similar to that of the monkey-eating species, but here the leading four vertebræ are pneumatic—the rest are nonpneumatic (Plate III, fig. 1, and Plate V). These vertebræ, including the pygostyle, are massive in structure, and present the usual ornithic characters of this part of the vertebral skeleton in the aquiline types.

Pithecophaga possesses a very large quadrilateral pygostyle, the lower portion of which seems to be a coössified terminal caudal vertebra, though now an inherent part of the bone and included in giving to it its peculiar shape. Superiorly and anteriorly the pygostyle possesses sharp edges, while the posterior one is thickened and rounded. Above its articulation in front, there is a small opening for the terminal of the spinal cord to enter, and below this, a double-faced articulation for the last free caudal vertebra. Just posterior to this the pygostyle is perforated from side to side by a smooth, subcircular foramen of some size (Plate III, fig. 2). The lower half, posteriorly, has the form of an isosceles triangle, with the apex above. Its sides are rounded, and its base is much thickened. Interiorly it is excavated, and the above-described foramen passes through the excavation, while the floor of the excavation exhibits a larger foraminal opening of an elliptical outline, with the major axis in the anteroposterior line.

In the harpy eagle a stumpy apophysis projects from the superoposterior angle of the pygostyle, while the foraminal openings are generally smaller. Throughout the falconine types of the world the pygostyle, while it may vary somewhat in form, possesses the same general characters, is always conspicuously large, and is commonly of a quadrilateral form.

Bones of the shoulder girdle, or pectoral arch.—Taking into consideration the marvelous power of flight possessed by this big eagle, we need experience no surprise at finding the bones composing this distinctive arch as in all birds of great strength, massive in structure (Plate IV). This is preëminently true, and probably no existing bird of its size possesses bigger and stronger bones in its shoulder girdle than an average eagle; to this statement our aquiline giant of the Philippines forms no exception. As is the case with all the bones of the trunk skeleton,

they are highly pneumatic in character, and consequently very light in weight for their size.

The os furculum, or fourchette, has the form of a very wide-spreading capital U; the lower part of the arch is not especially strong, while it rapidly increases in size from below upward, to terminate in immense, free clavicular extremities. Either of these is much compressed from side to side, with its great superior end accurately molded, externally, to the mesial head of the scapula of the same side. When duly articulated, its apex barely comes in contact with the anteromesial angle of the head of the scapula of the same side.

The clavicular limbs of the furculum are greatly compressed from side to side, and the edges thus formed are sharp, especially the mesial ones. There is but small evidence of a hypocleidium, and the entire bone is powerfully curved backward and upward. Its pneumatic foramina are principally situated in the concavities of the upper clavicular extremities, upon their moderately shallow outer concavities, on that part of the bone, upon either side, which goes to complete the foraminal passage among the heads of the three bones of this girdle.

The os furculum in the skeleton of our subject agrees very well with the corresponding bone in the harpy eagle; though in the latter species the free clavicular ends are more extensively rounded off than they are in the case of the Philippine bird. Our white-headed eagle possesses a more delicately fashioned furculum, while in such a form as *Thalassoaëtus pelagicus*, of Korea, the clavicular free ends are enormously developed; but, owing to the high degree of pneumaticity, the bone, as a whole, is extremely light in weight. Doubtless other eagles present still other differences, not only in the furculum, but also in the remaining bones of the girdle.

When articulated as in life, the coracoids in *Pithecophaga* do not meet in the median line, being separated by an interval of several millimeters. Either bone is very massive in form; but is light in weight, owing to the high degree of pneumaticity it enjoys. All of its parts are conspicuously developed, the broad scapular process being perforated by a foramen piercing it from before backward. There may be pneumatic foramina of some size on the mesial aspect of the big head of the bone and still others on its outer aspect. A sternal extremity is considerably expanded, the bone in articulation extending beyond the sternum laterally. Here it is much compressed from before backward, and thickened at its mesial angle.

The harpy eagle possesses coracoids very similar to those of *Pithecopphaga*, while in the American white-headed species the head of the coracoid is much compressed from side to side.

In agreement with the other bones of its pectoral arch, *Pithecopphaga* possesses a scapula of great size and unusual strength. As in the case of the coracoid and the furculum, it is highly pneumatic, the foramina for the admission of air into its interior being found on the ventral aspect close to the head of the bone. The head is broad from side to side and somewhat compressed from above downward; at its outer angle there is an elliptical articular surface that constitutes about one-third of the glenoid cavity, while at the mesial angle a big quadrilateral process projects forward for the attachment of the coracoscapular ligament. The neck of the bone is broad and thick; the borders are rounded off. This part constitutes about one-third of the blade; posterior to it we have the curved scimitarlike blade of the bone. This is carried backward to a blunt point, the outer border being rounded, and the mesial one having a thickened edge; the latter commences abruptly near the middle point of the bone as a whole. From head to apex this scapula presents a uniform and gentle curvature in the plane of the bone's blade, the concavity of the curve being along the outer border.

The harpy eagle has the distal moiety of a scapula very broad, with the outer margin sharp, but the inner one rimmed pretty much as we find it in the monkey-eating species. In the golden eagle the terminal part of the blade is distinctly truncated, and the entire bone is much compressed from above downward. This is also true of the scapula in our white-headed bird; here the blade is extremely narrow and is drawn out posteriorly to a truncated apex. In this species it does not seem to be especially pneumatic. The Korean eagle has a scapula resembling that bone in the golden eagle.

These birds—*Pithecopphaga* forms no exception to the rule—possess a big sternum of extraordinary capacity. Ventrally it is one deep basin from side to side as well as lengthwise. Down the middle line there is a row of scattered foraminal openings to admit air during the life of the individual. Its xiphoidal border is at right angles to the long axis of the bone and presents but a shallow concavity for its middle third. Well within this border, upon either hand, there is an elliptical foramen of no great size. Seven facets occur upon each costal border, with a great many pneumatic foraminal openings among them. Their interarticular cavities are very shallow. On the outer aspect of

the body of this sternum, at the anterosuperior angle and including the distance occupied by the first four hæmapophysial articular facets, there is a marked concavity which is the continuation of the costal groove of the same side. Its lower boundary is curved, with the convexity toward the keel (Plate IV). The keel is not deep by any means and is continued only two-thirds the length of the body, its lower border being uniformly convex. Anteriorly, the carinal angle is rounded off, the concave, anterior border above it being sharp for its lower half and flat for its upper, terminating superiorly in a stumpy manubrium, which is truncated anteriorly, leaving, as it were, a small, triangular surface, with the angle below in the middle line. The deep coracoidal grooves are remarkably well defined in front, in the middle line, at which point they decussate to some extent.

The external surface of the sternal body, upon either side of the carina, is smooth, and the line of the pectoral muscle is but faintly defined. Occasionally we find in the body of the sternum of this and other eagles one or two small, sporadic foraminal openings, just as though a bird shot had made a perforation and the wound subsequently healed. I find a rather large, nearly circular one of these in the sternum of the harpy eagle, it being situated on the right side of the body of the bone, near its middle. In this species the sternum is somewhat smaller than the one just described; but, ventrally, it presents the same profound concavity, with fewer evidences of pneumaticity, however. The xiphoidal elliptical foramina, one upon either side, are very much larger; and this extremity of the bone has an increased width due to the lateral extension of the xiphoidal portion, which is well seen upon lateral view (Plate V). There is the same number of articular facets upon either costal border as we described for *Pithecophaga jefferyi*—indeed, all eagles seem to have the same number. The Korean eagle lacks any foraminal openings in the xiphoidal end of the bone, and the sharp border there is entirely lacking in notches, being wholly at right angles to the carina, which fails to run out to it by at least 2 centimeters. Within the thoracic cavity of the body of the bone foraminal perforations occur not only down the middle line of the bone to a point opposite the last pair of facets on the costal borders, but likewise in a great area in front and along both sides to a similar point. The coracoidal grooves decussate in this eagle, as they do in the white-headed species, and they are invariably of some considerable depth. In the latter bird there is also an absence

of the xiphoidal foramina, and that border presents a squarish prolongation of no great size in the middle line; it possesses all the other aquiline characters of this bone.

In the bearded vulture, of Europe, the body of the sternum is square in outline, and not a parallelogram as in eagles; its coracoidal grooves do not decussate, and it has but six pairs of costal ribs. In fact, the bone is that of a big vulture, and in no way suggests that of an aquiline species of any sort.

The pectoral limb.—Plates VII and VIII. It has long been a well-known fact that all big raptorial birds possess limbs of great size, power, and proportions. This is what we would usually look for when we come to consider their habits and the character of their prey. It also explains the fact that most of the bones of their limbs enjoy a very perfect state of pneumaticity; the skeleton of the foot, however, often forms an exception to this condition. Possibly, in some of our eagles, even the foot bones may be pneumatic; they appear to be so in some degree in our white-headed species, but surely not in the golden eagle. True vultures, almost without exception, possess a skeleton presenting a lightness and an extremely perfect pneumaticity unequaled by any other family of birds. *Gypaëtus* forms a partial exception to this rule, in so far as the skeleton of its feet is concerned; but this bearded species approaches the eagles, while our American vultures are birds that practice long-sustained and steady flight, and do not capture their prey—hence a more perfect aëration has evolved in them.

In the different species of eagles, in so far as I have examined them, the humerus varies but little in form or in general characters. It is invariably a large and thoroughly pneumatic bone, and to this statement *Pitheophaga* presents no exception. It has a length of about 20 centimeters; and, taken as a whole, its shaft presents the "sigmoid curve" in a nearly perfect degree. Rather less than its middle third is very smooth and quite cylindrical in form. Its radial crest is short and triangular in outline, while the ulnar tuberosity is very conspicuously developed and arches over—to some considerable extent proximally—the deep pneumatic fossa, in which may be seen the pneumatic foramina of very large size, but generally few in number. There is also a row of these foramina along the base of the smooth, elliptical head of the bone on the anconal side; they are of no great size in this locality. A very distinct elongate elliptical area—raised above the general surface—with its major axis parallel to the bone's shaft, may be seen at the distal

base of the radial crest on the palmar aspect of the expanded proximal end of this humerus; it denotes the place of insertion, in life, of the pectoralis muscle, and is found in the same location in all true eagles.

All of the ornithic characters seen in the avian humerus, in so far as falconine species go, are to be found at the distal end of this bone of our present subject, and each and all of them are unusually prominent. This applies especially to the two articular tubercles, the trachial fossa, and the tendinal grooves on the anconal aspect. In the aforesaid fossa a few, small, scattered, pneumatic foramina may be observed, especially just beyond the radial and ulnar tubercles.

The radial crest of the left humerus of this individual exhibits the results of some previous disease, and it has manifested itself in the form of quite an extensive exostosis. The ulnar crest is carried down onto the shaft for a distance of about a centimeter as a sharp and distinct border; while at its middle we note a small foraminal perforation, with a groove leading into or out of it, on the palmar surface of the proximal, expanded extremity of this bone.

This foraminal perforation is absent in the radial crest of the humerus of the harpy eagle, and the crest itself is of a triangular outline (Plate VII, fig. 2); while otherwise, in all other matters, the two bones are notably similar in these two eagles. However, in the harpy it may be noted that the caliber of the shaft is greater and presents less sigmoidal curvature.

In the Korean eagle (*Thallasoaëtus pelagicus*) the humerus is fully 1.5 centimeters longer than it is in *Pithecophaga jefferyi*; it is also straighter and somewhat slenderer. Its large, triangular, radial crest extends farther down the shaft, while in all other respects the two bones are very similar. Curiously enough—the above fact notwithstanding—the skull of the Korean bird is neither as large nor as massive as is the skull of the eagle of the Philippines. This difference is possibly due to a longer wing in the former species; but the material is not at hand at this writing either to prove or to refute any such statement.

In September, 1918, I published an account of *Pithecophaga jefferyi*, illustrated by natural-sized figures of its head and foot.¹ In that article I made the statement that the species was the largest of all existing raptorial birds. Possibly this may be so; while, upon the other hand, the big eagle of the Orient (*Thalla-*

¹ Am. Forestry 24 (1918) 555-557, 2 figs.

soaëtus pelagicus), found in Kamchatka and Japan as well as in Korea, may be a bigger bird in some respects. Sharpe included the Old World vultures in the true raptorial group. In the genera *Vultur* and *Serpentarius* there are some big species the comparative weights and proportions of which have never been taken for a series of living specimens or compared with the corresponding data on *Pithecophaga jefferyi*.


I have never compared the wedge-tailed eagle, *Uroaëtus audax* Lath., of Australia and Tasmania, with our present subject; but I am inclined to believe that it is not so large a bird.

The radial crest of the humerus of the white-headed eagle of the United States is also triangular in outline; while in *Aquila chrysaëtos canadensis* this feature of the bone under consideration is not so lofty and, while triangular in general outline, it extends very much farther down the shaft of the bone. Here, too, the osseous emargination of the pneumatic fossa is broader and more extensive, thus closing in upon the true cavity, though in no other way diminishing its capacity.

The bearded vulture of Europe has a humerus fully one-third larger than that bone in *Pithecophaga*, and its characters are very similar, the most striking departure being the shallow pneumatic fossa in the former species, with all of its foramina merged into one subcircular foramen.

In the antibrachium of *Pithecophaga* both the ulna and the radius exhibit some degree of curvature between proximal and distal extremities. Air gains access to their interiors through minute foramina at the proximal and the distal end of each; at the latter situation they articulate in the usual manner with the radiale and the ulnare of the carpus, bones that here present the avian characters usually seen among the eagles. The radius has an extreme length of some 20.5 centimeters, and the ulna is about 2 centimeters longer than this. The latter bone has a double row of osseous papillæ down its cylindrical shaft; these, as in other birds, are for the attachment of the quill butts of the secondary feathers of the wing. There are ten in each row, and all, to the last pair at either end, are opposite each other. The anterior third of the radius is subcylindrical in form, while the remainder of the shaft is trihedral on section. Its "radial tuberosity" is concaved in the center, with the inner margin sharp. Our harpy eagle skeleton lacks the bones of the forearm and manus.

Thalassoaëtus pelagicus has the radius and the ulna much longer than the monkey-eating eagle, and each is markedly



slenderer. We are also to notice that the papillæ on the shaft of the latter are closer together. Ten pairs of them appear to be present, and the ulna in this bird has an extreme length of 24.3 centimeters.

America's golden eagle departs from others examined, in that the humerus and the femur are the only pneumatic bones of the pelvic and pectoral limbs.

Unfortunately, I have not at hand the skeleton of manus either in the case of the harpy or of the species here being osteologically considered; so that a description of these parts will have to be undertaken by someone else, when such material falls into the hands of science. Very likely, in other published papers of mine, descriptions of these parts of the skeleton in other species of eagles will be found, either of fossil or existing species.

The pelvic limb.—Plate VII, fig. 1; and Plates IX, X, and XI. *Pithecophaga jefferyi* possesses a big femur, which is permeated by air in all of its parts. There is an extensive group of pneumatic foramina in the deep popliteal concavity, and another large opening on the proximal end of the bone anteriorly, at the termination of the trochanter major; it is bounded internally by the linea aspera. Caput femoris is sessile, with an extensive pit for the ligamentum teres. The summit is smooth and convex from before backward, and concave from head to the trochanter, which latter rises above the summit of the bone. It is very broad and rough on its external surface. Passing to the shaft, we find that to be very stout and uniformly arched, the convexity being in front. For its middle third it is subcylindrical in form and very slightly roughened throughout.

Distally the condyles of this femur are enormous with very prominent articular surfaces. The side of the inner condyle is, for the most part, flat and smooth, while the outer one is slightly roughened and presents a conspicuous tuberosity. As usual, this condyle is vertically divided posteriorly, in that it may articulate with the head of the fibula of the leg. This femur has an extreme length of about 13.2 centimeters, or 2 millimeters more than the length of the femur of a harpy eagle; but the little that the harpy lacks in length in this bone it amply makes up in stoutness; and, apart from this general stoutness, there is no specific difference worthy of notice or description.

The femur of the golden eagle is of about the same length as the two just noticed; but it is a far slenderer bone, with the elliptical pneumatic foramen at its proximal end very conspicuous, and the muscular lines on the shaft are likewise so. The poplit-

eal cavity is shallow in the femur in this species, as it is in some other eagles. *Haliaetus leucocephalus* also has a slenderer femur, while *Thalassoaetus pelagicus* has one of moderate proportions—that is, not as long or as stout as in *Pithecophaga*, and the shaft is slightly more curved. In the femur of this species the noteworthy characters consist in the great prominence of the tubercle on the outer condyle and the unusual depth of the pit on the caput femoris for the ligamentum teres.

Air does not enter so extensively into the bones of the leg in *Pithecophaga* as it does in the case of the femur. Still, they are to some considerable degree pneumatic; for, upon ordinary maceration, the bones largely whiten, though not nearly as much as does the femur, while in no part do they turn fatty yellow, as happens to the metatarsus and toe bones after similar treatment.

The tibiotarsus in *Pithecophaga* measures some 20.4 centimeters in length, and the fibula measures 15.8 centimeters (compare Plate VII, fig. 1, and Plate IX, figs. 2 and 3). The first-named bone is nearly straight from end to end, being but very slightly arched to the front. For its distal third it is markedly flattened in the anteroposterior direction—less so above, where it is flat for its anterior surface and sides, the shaft being here trihedral on section. Distally the condyles are very much suppressed posteriorly and correspondingly pronounced in front, where the valley between them is deep. Above them, to the inner sides, the tendinal groove is of great depth; it is very distinctly defined as to its boundaries, and the oblique “tendinal bridge” is strong and similarly characterized.

Proximally the raised ridge for articulation with the fibula has a length of 3.5 centimeters and lies wholly within the upper third of the shaft, which here is very flat and smooth. Above this we note the low and short cnemial processes, separated by a wide and rather deep valley. The ectocnemial process terminates in a rather blunt, down-turned hook, extending but very slightly above the summit of the bone. The latter slopes to the outer side, and presents a prominent, rounded, articular tubercle near the head of the femur, which may or may not be especially noticeable in this bone in other eagles. At the sides, as well as posteriorly, the summit bulges out over the shaft, being most thickened along its inner course, beyond which point a concavity occurs, bounded in front by the entocnemial process.

Turning to the fibula, it is to be observed that its shaft below the fibular ridge of the tibiotarsus is long and slender, being much compressed anteroposteriorly, opposite the middle third

of the companion bone of the leg. Below this, it runs onto the shaft, and here the contact almost amounts to a direct fusion with it. At its lowest point it is not over 3.5 centimeters above the lower margin of the external tibial condyle. All diurnal Raptores possess fibulæ of greater or less length; especially do we find this to be the case in *Pandion*. Superiorly, in our subject, the fibula is much compressed from side to side, with its head produced posteriorly. Its entire summit, convex from before backward, is an articular facet for the outer condyle of the femur.

Pithecophaga possesses a rather large patella, which is elongate from side to side, in which direction the surface is convex, while posteriorly it is concave above and doubly concave posteriorly for articulation with the condyles of the femur. Inferiorly, the surface is limited and flat. Sometimes, as in the case of our present subject, there is a small, circular ossification in the tendon of the muscle, several millimeters below the true sesamoid of the knee joint; it occurs in both limbs.

Eagles exhibit very considerable variation in their leg bones, but more in the tibiotarsus than in the fibula. For instance, in the harpy the latter bone is more than a centimeter shorter than it is in the Philippine bird now being described, while at the same time the shaft is very conspicuously flattened from before backward; at the same time, this flattening is associated with a marked increase in the shaft's width. With respect to the fibula of the harpy, it broadens below the articular ridge, and is grooved for the passage of the muscle that passes over it (Plate VII, fig. 1). In the white-headed eagle the cnemial processes of the tibiotarsus are greatly reduced in all particulars, and to a lesser extent this is also true of the Korean eagle; the fibula is very long in the species.

With respect to the golden eagle (*Aquila chrysaëtos canadensis*), the bones of the leg are nonpneumatic for their entire length below the proximal extremities, the shaft of the tibiotarsus in this species being curved from end to end, the concavity being along the inner or mesial aspect.

Skeleton of the foot.—Plates X and XI. As already noted, the tarsometatarsus and other bones of the foot in this eagle are entirely nonpneumatic, while in some other forms the reverse of this is the case (*Halizætus leucocephalus*). Irrespective of species the tarsometatarsus possesses the same general characters throughout the group, and its form is very characteristic. All this part of the skeleton in the harpy was left in the skin of

the mounted specimen at the United States National Museum, so that no comparison can be made here along such lines with the corresponding bones in our subject. In the latter the bone has a length of about 12 centimeters and an average breadth of 2 centimeters. Its summit exhibits two shallow articular facets for the condyles of the tibiotarsus. An intercondylar tubercle stands between them on the anterior margin, the width of the surface being double its depth, while posteriorly is to be noted a hypotarsus of the usual aquiline type. This consists of a quadrilateral process standing out at right angles to the bone—its hinder border being considerably thickened—and its base opposite the inner articular concavity at the summit. Opposite the outer one is another process, it being stumpy and much aborted; between the two is a wide, shallow valley.

Posteriorly the shaft of this tarsometatarsus is smooth, broad above, and somewhat narrower distally. It is concaved throughout its entire extent, its margins being more or less sharpened, except where the accessory metatarsal is swung by ligament about a centimeter above the inner trochlea. The outer aspect of the shaft is flat, being broad at the middle third, and tapering somewhat to the ends. It is the posterior margin of this surface that forms the inner sharpened border of the posterior aspect alluded to above. Anteriorly the surface is much twisted upon itself, the upper half being concaved longitudinally and convexed for the rest of the extent, the two merging into each other. At the upper third, anteriorly, we note the usual twin perforations a short distance below the summit; and below them, to the outer side, is the elongate tubercle for muscular insertion.

Distally there are three very substantial trochleæ for the basal phalanges of the toes, the inner one being the largest and at the same time the lowest on the shaft. Slightly up on the shaft, between the outer and middle condyle, is to be noted the usual foraminal perforation present in nearly all birds; it transmits the flexor tendon of the outer toe and, it is said, the anterior tibial artery.

The accessory metatarsal is of considerable size, is flattened and somewhat twisted upon itself, and supports distally a very large, transversely disposed, trochlear facet; the latter is devoted to the articulation of the basal joint of the hallux, which is a digit of enormous power and strength, as will be appreciated through a glance at Plate X. Equally powerful are the joints and the talons of the anterior toes, the arrangement and pro-

portions of which are upon the usual ornithic plan of the aquiline pes, with the osteological characters I have often described before, of existing forms as well as of fossil eagles.

CONCLUSIONS

Coming to the relationships of *Pithecophaga jefferyi*, with respect to other representatives of the same group and in the light of the osteological material above described and compared with its skeleton, I am of the opinion that its nearest ally, in so far as we are at present acquainted with the morphology of other eagles, is the harpy eagle (*Thrasaëtos harpyja*).

Sharpe² makes a very different disposition of this species; he places it between *Circaëtus* and *Spilornis*, of the Aquilinæ (Subfamily V); while the harpy eagle we find arrayed with the Buteoninæ (Subfamily III), following *Harpyopsis*, the next following Subfamily (IV) being the Gypaëtinæ (*Gypaëtus barbatus*). The osteology of *Pithecophaga* surely does not support this arrangement.

PREVIOUS PAPERS BY THE AUTHOR ON THE OSTEOLOGY OF THE EAGLES AND THEIR ALLIES

[Papers on the owls and the vultures are not included.]

1. On the ossicle of the antibrachium as found in some of the North American Falconidæ. *Bull. Nutt. Orn. Club* 6 (1881) 197-203.
2. On the free post-pubis in certain of the Falconidæ. *Auk* 3 (1886) 133, 134. 1 text figure.
3. Osteology of *Circus hudsonius*. *Journ. Comp. Med. and Surg.* 10 (1889) 126-159. 17 text figures.
4. A peculiar character referable to the base of the skull in *Pandion*. *Auk* 8 (1891) 236, 237.
5. Some comparative osteological notes on the American kites. *Ibis* VI 3 (1891) 228-232.
6. On a collection of fossil birds from the Equus beds of Oregon. *Am. Nat.* 25 (1896) 303-306. Plates.
7. Fossil birds from the Equus beds of Oregon. *Am. Nat.* 25 (1891) 818-821.
8. Tertiary fossils of North American birds. *Auk* 8 (1891) 365-368.
9. A study of the fossil avifauna of the Equus beds of the Oregon Desert. *Journ. Acad. Nat. Sci. Philadelphia* 9 (1892) 389-425, pls. 15-17.
10. On cases of complete fibulæ in existing birds. *Ibis* VI 6 (1894) 361-366, figs. 1, 2.
11. Some of the "outliers" among birds. *Pop. Sci. Monthly* 44 (1895) 760-780. 10 text figures (not osteological).
12. On the affinities of *Harpagornis*. *Trans. New Zealand Inst.* 28: 665.
13. Observations on the classification of birds. *Proc. Acad. Nat. Sci. Philadelphia* (1898) 489-499. Illustrated. (Osteology largely used.)

² A Hand-list of the Genera and Species of Birds. London 1 (1899) 265.

14. An arrangement of the families and higher groups of birds. *Am. Nat.* 38 (1904) 833-856, text figs. 1-6. (Osteology largely used.)
15. Where the skeletons of American birds may be studied. *Auk* 26 (1909) 217-218.
16. Osteology of birds. *Bull. N. Y. State Mus.* 130 (1909) 367 pp. Education Department Bulletin No. 447. (This book contains many cuts and plates devoted to the osteology of the Falconidæ and has been particularly useful in studying the skeleton of the eagles.)
17. Review of the fossil fauna of the desert region of Oregon, with a description of additional material collected there. *Bull. Am. Mus. Nat. Hist.* 32 (1913) 123-178, pls. 9-43, figs. 1-578.
18. Further studies of fossil birds, with descriptions of new and extinct species. *Bull. Am. Mus. Nat. Hist.* 32 (1913) 285-306, pls. 51-59, figs. 1-94.

ILLUSTRATIONS

[All the figures are reproductions of photographs by the author made direct from the specimens.]

PLATE I

- FIG. 1. *Pithecophaga jefferyi*, adult; right lateral view of the skull, natural size. All the bones of this bird figured on the plates are of two individuals. The specimens were received from Mr. R. C. McGregor, of the Bureau of Science, Manila, P. I.
2. The skull shown in fig. 1, seen directly from above, natural size.

PLATE II

- FIG. 1. *Haliaeetus leucocephalus*, white-headed eagle, sex?, adult; cranium, direct view from above, very slightly reduced. Median longitudinal diameter measures 11.1 centimeters in this specimen. No. 19278, United States National Museum collection. This skull belongs to the skeleton of the specimen used throughout this paper.
2. *Aquila chrysaetos*, female, adult; cranium, direct view from above, very slightly reduced. Median longitudinal diameter measures 11.9 centimeters in this specimen. No. 18802, United States National Museum collection.
3. *Morphnus guianensis*, sex?, adult; cranium, direct view from above, very slightly reduced. Median longitudinal diameter measures 9 centimeters in this specimen. No. 18468, United States National Museum collection.

PLATE III

[All figures of Plate III natural size and from the same species, *Pithecophaga jefferyi*.]

- FIG. 1. The six caudal vertebræ (*a* to *b*) arranged in normal sequence and viewed from above; *a*, anterior one of chain.
2. Pygostyle, right lateral aspect. Lower part pierced by a foramen.
3. Fifth cervical vertebra, seen from above.
4. Mandible, seen from above.
5. Anterior aspect of ninth cervical vertebra.
6. Trachea, twisted and distorted through drying; fragments of bronchial tubes at inner end.
7. The atlas, posterior aspect.
8. Anterior view of axis; neural spine directed downward.
9. Sclerotal circlets of the eyes; elements as they occur or are arranged in life.
10. Hyoid arches viewed from above, with larynx in situ; the latter removed at a point seen at the outer end of the trachea in fig. 6.

PLATE IV

Pithecophaga jefferyi; right lateral view of the trunk skeleton, including bones of the shoulder girdle, reduced about one-third. The pygostyle and the six caudal vertebræ preceding it have been removed.

PLATE V

Thrasaëtos harpyja, harpy eagle; right lateral view of the trunk skeleton, including bones of the shoulder girdle, reduced less than one-half. Length of sternum in the specimen equals 13 centimeters. No. 225806, United States National Museum collection; a specimen from Brazil.

PLATE VI

Pithecophaga jefferyi; trunk skeleton, seen upon direct dorsal view, with the shoulder girdle in situ, reduced about one-third. The pygo-style and the six caudal vertebræ preceding it have been removed.

PLATE VII

- FIG. 1. *Thrasaëtos harpyja*; anterior aspect of the right tibiotarsus and fibula, slightly reduced. From the same specimen as Plate V.
 2. *Thrasaëtos harpyja*; anconal aspect of left humerus, slightly reduced. From the same specimen as Plate V.

PLATE VIII

- FIG. 1. *Aquila chrysaëtos*, golden eagle; anconal aspect of right humerus. No. 18802, United States National Museum collection. Length of bone, about 18.2 centimeters.
 2. *Thrasaëtos harpyja*; anconal aspect of right humerus. From the same specimen as Plate V.
 3. *Pithecophaga jefferyi*; anconal aspect of right humerus, reduced about one-third. Bone in life measures about 19.7 centimeters in length.

PLATE IX

- FIG. 1. *Pithecophaga jefferyi*; left femur, posterior aspect. Extreme length of bone in specimen, about 13 centimeters. Bone entirely pneumatic.
 2. *Pithecophaga jefferyi*; right tarsometatarsus and fibula, viewed on direct anterior aspect. Length of tarsometatarsus in specimen, about 23 centimeters.
 3. *Pithecophaga jefferyi*; left tarsometatarsus and fibula, viewed on direct outer aspect.

PLATE X

Pithecophaga jefferyi; skeleton of the right foot, mesial aspect, natural size.

PLATE XI

- FIG. 1. *Halizætus leucocephalus*; skeleton of right foot, inner aspect, natural size. No. 19278, United States National Museum collection.
 2. *Halizætus leucocephalus*; skeleton of left foot, outer aspect, natural size. The same bird as in fig. 1.

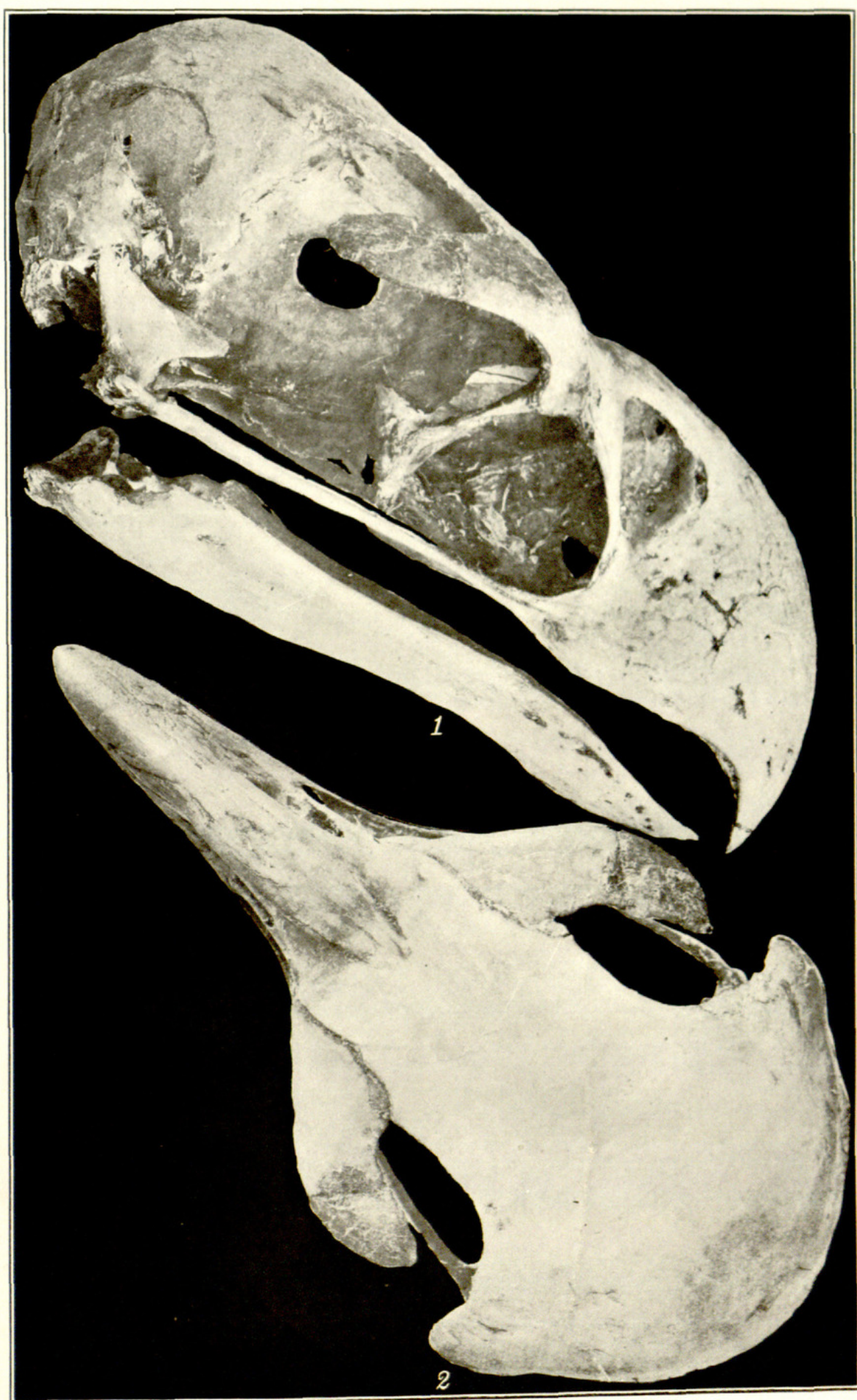


PLATE I. PITHECOPHAGA JEFFERYI.

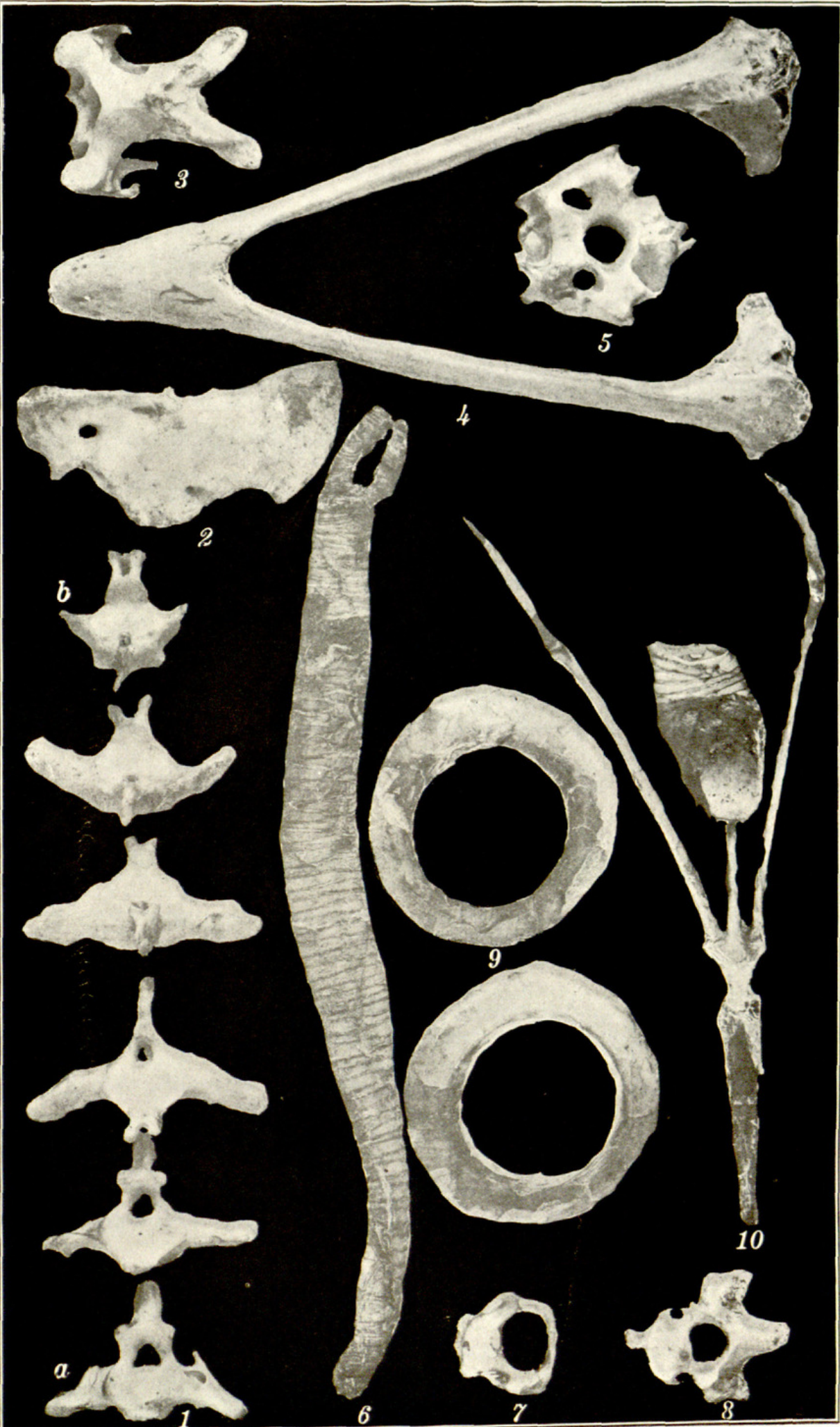

PLATE III. PITHECOPHAGA JEFFERYI.

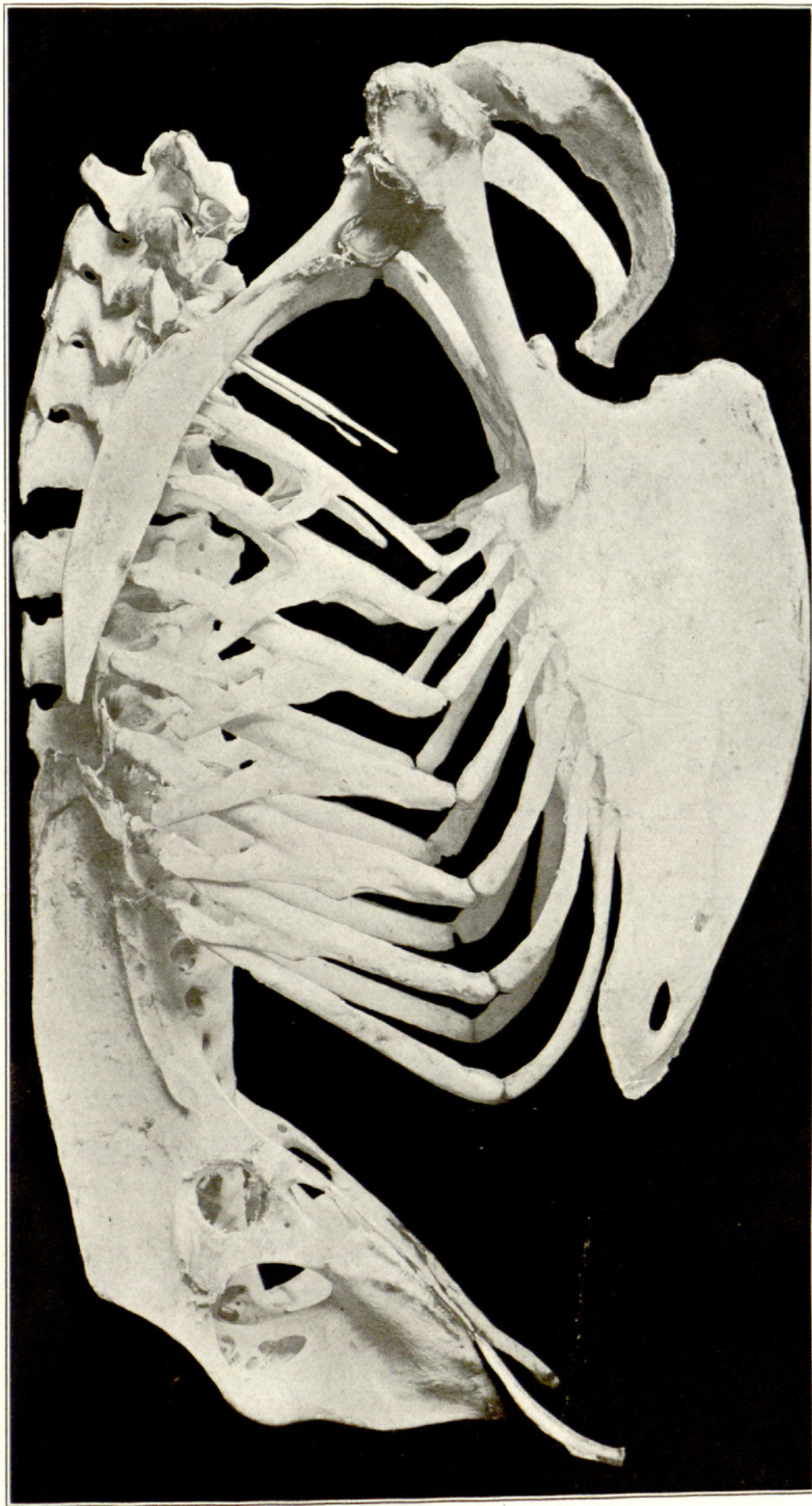


PLATE IV. TRUNK SKELETON OF PITHECOPHAGA JEFFERYI.

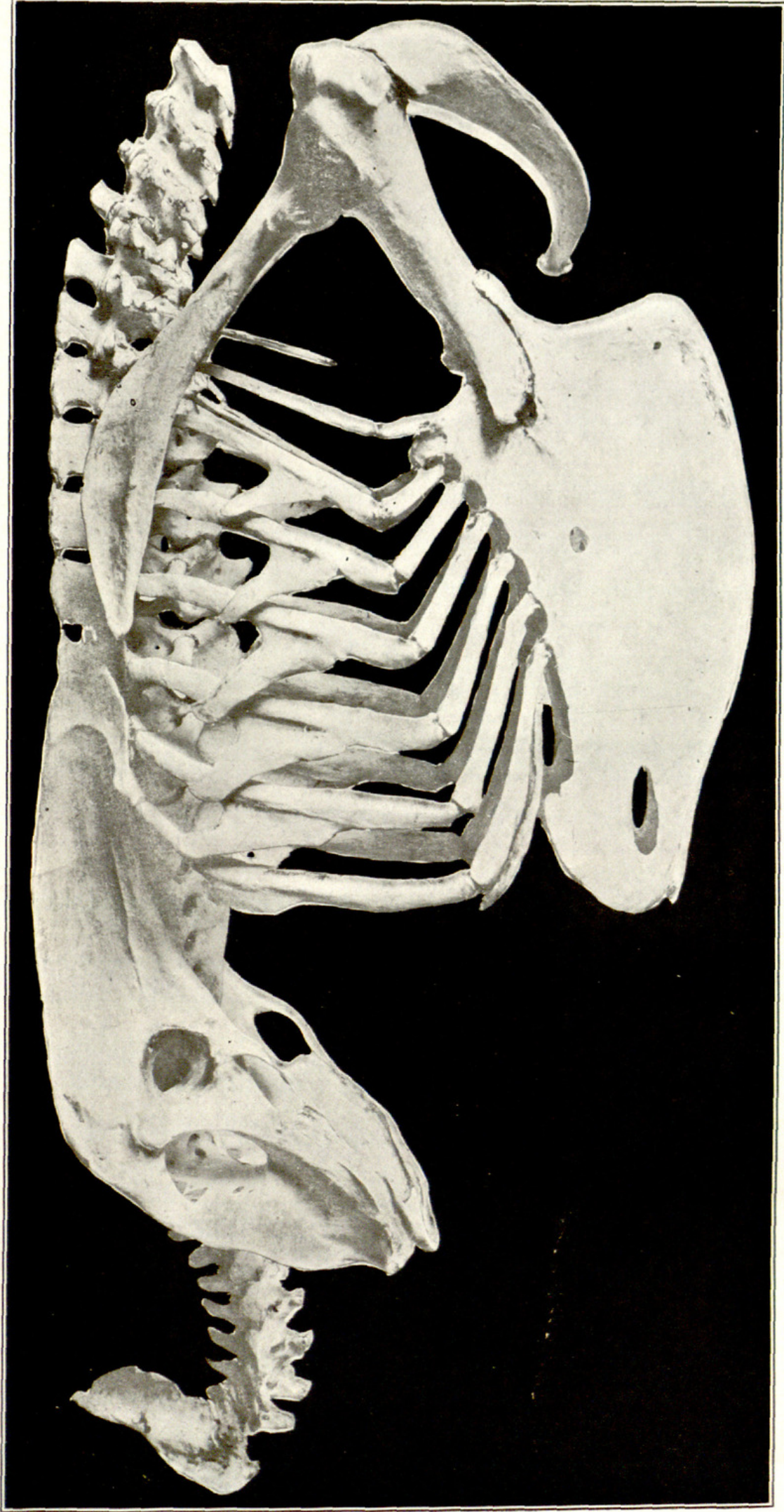


PLATE V. TRUNK SKELETON OF THRASAËTOS HARPYJA.

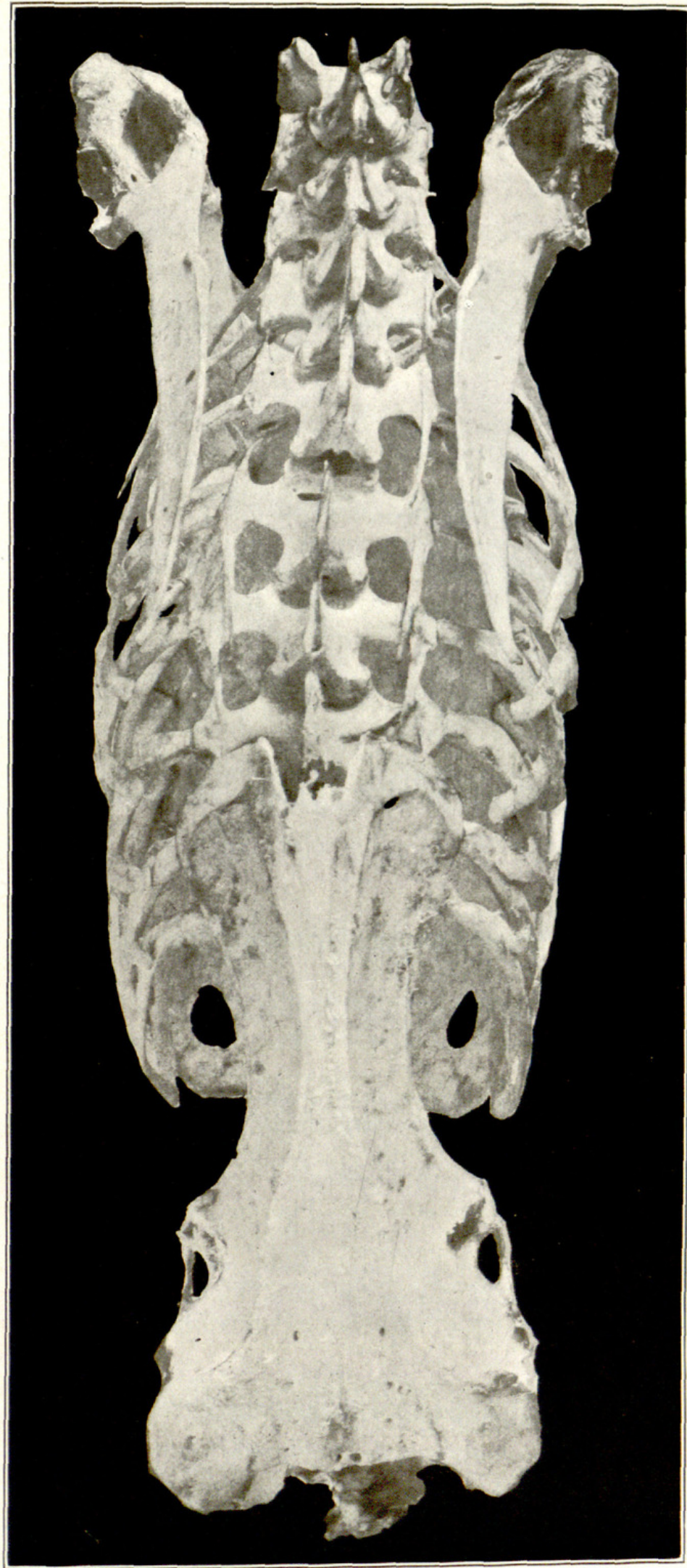

PLATE VI. TRUNK SKELETON OF PITHECOPHAGA JEFFERYI.

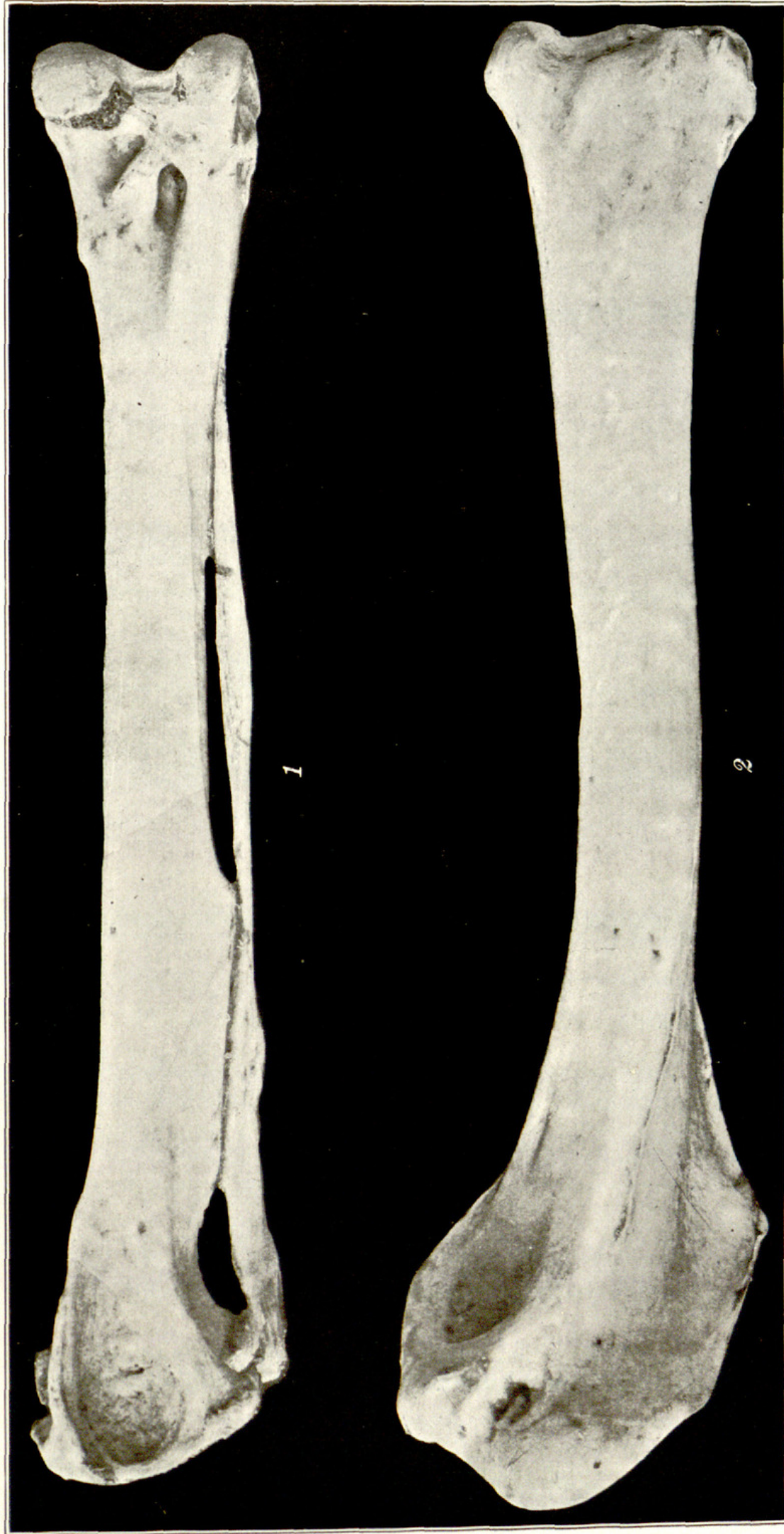

PLATE VII. THRASAËTOS HARPYJA.

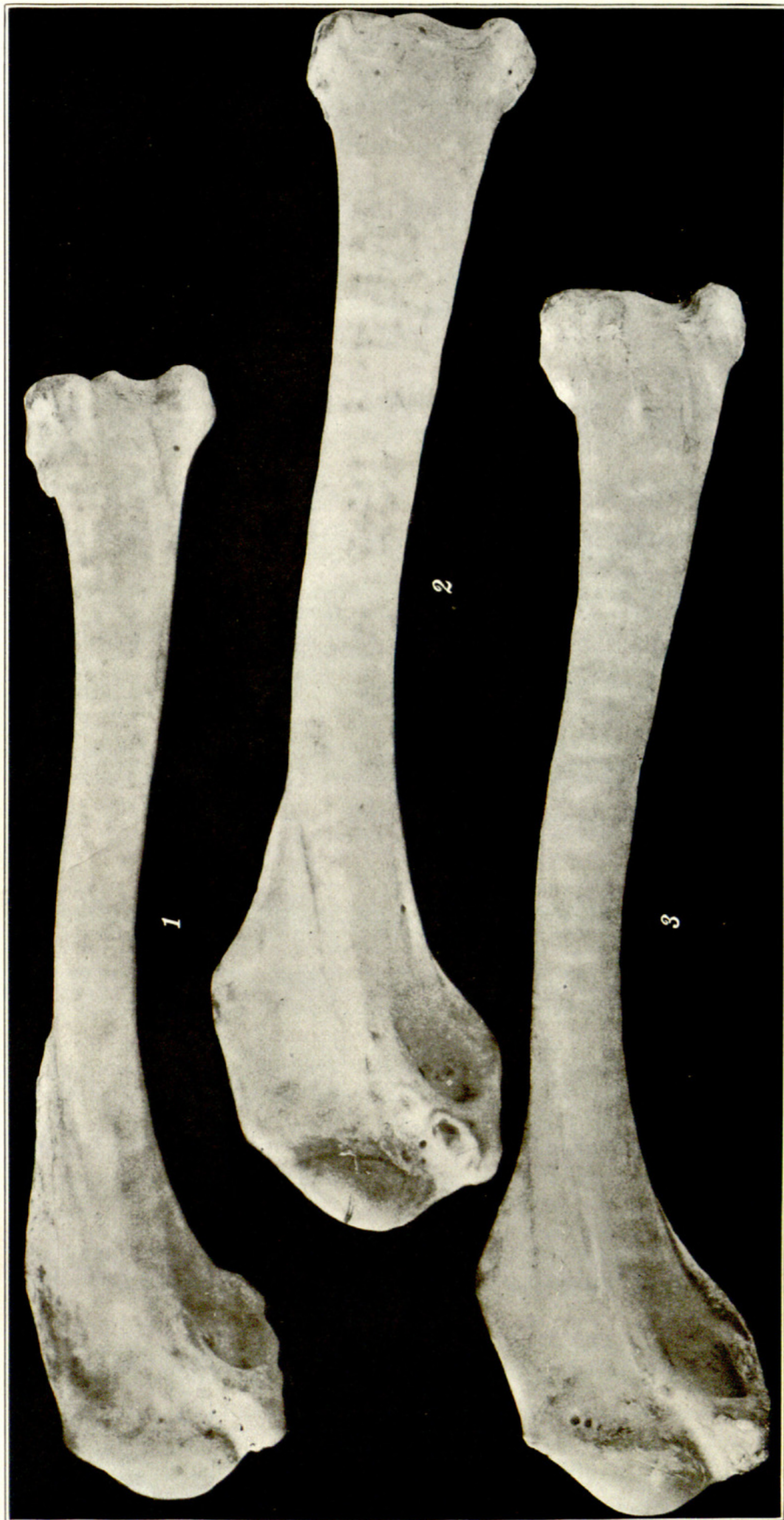

PLATE VIII. HUMERI OF THREE EAGLES.

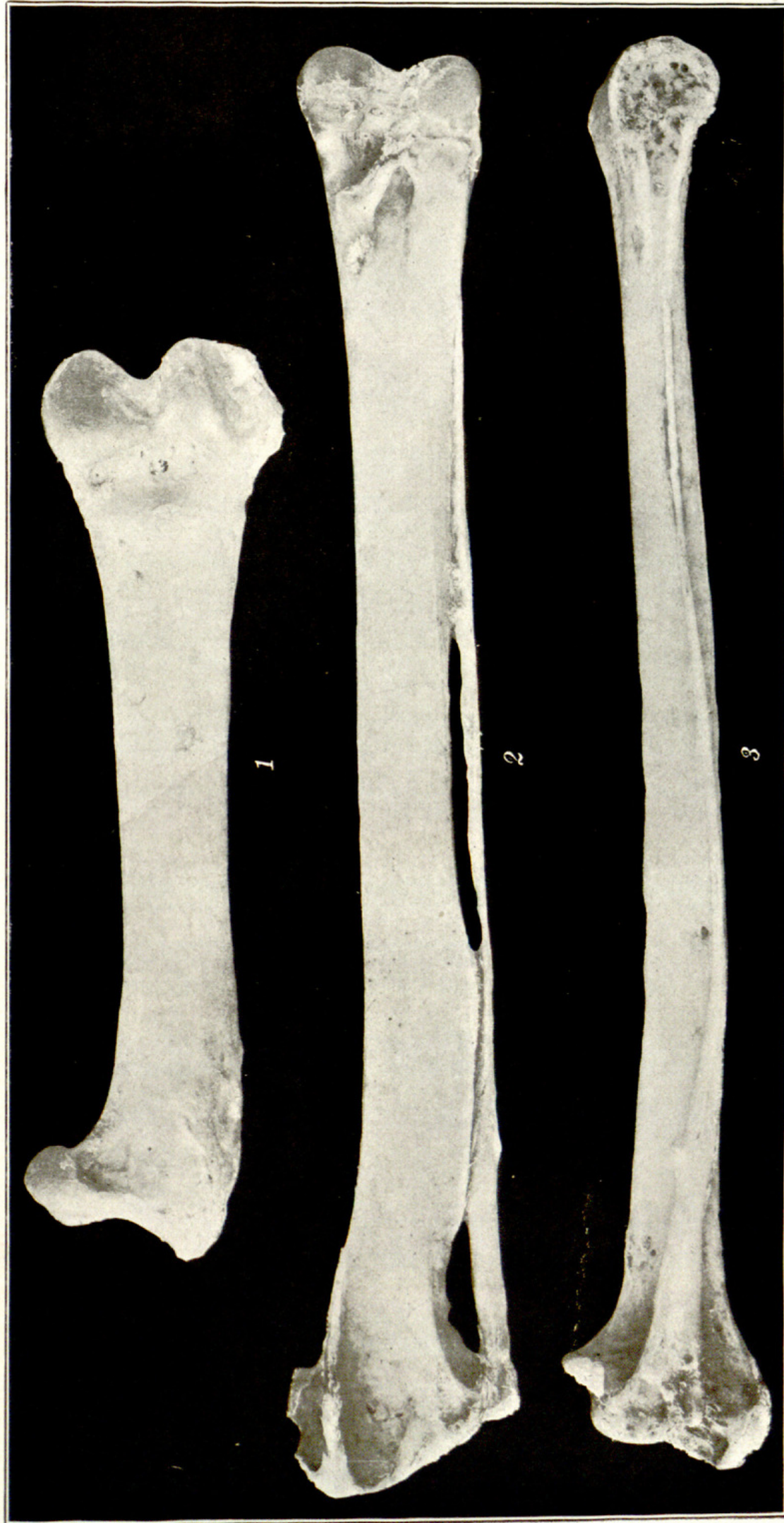

PLATE IX. LEG BONES OF PITHECOPHAGA JEFFERYI.

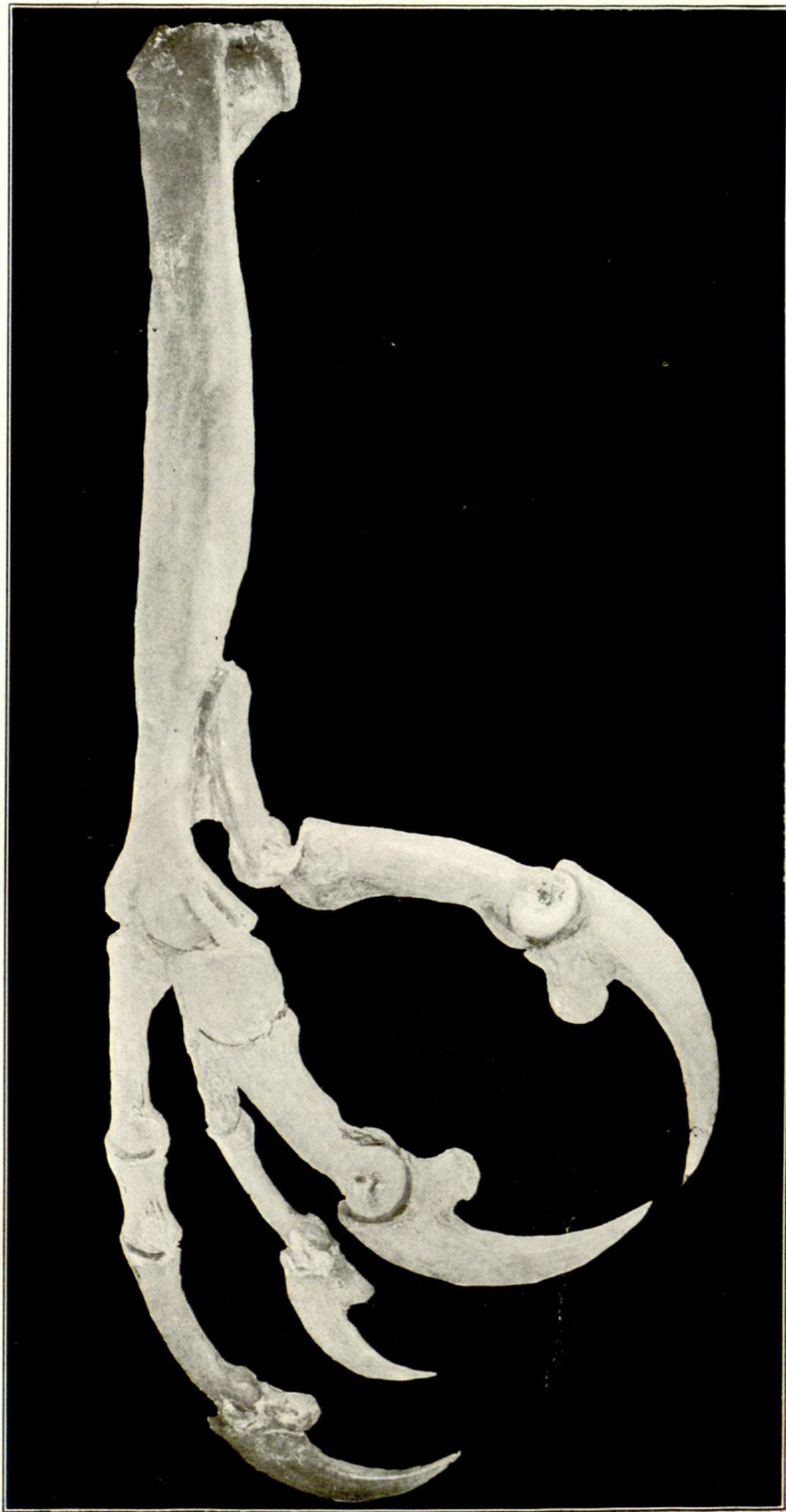

PLATE X. FOOT OF PITHECOPHAGA JEFFERYI.

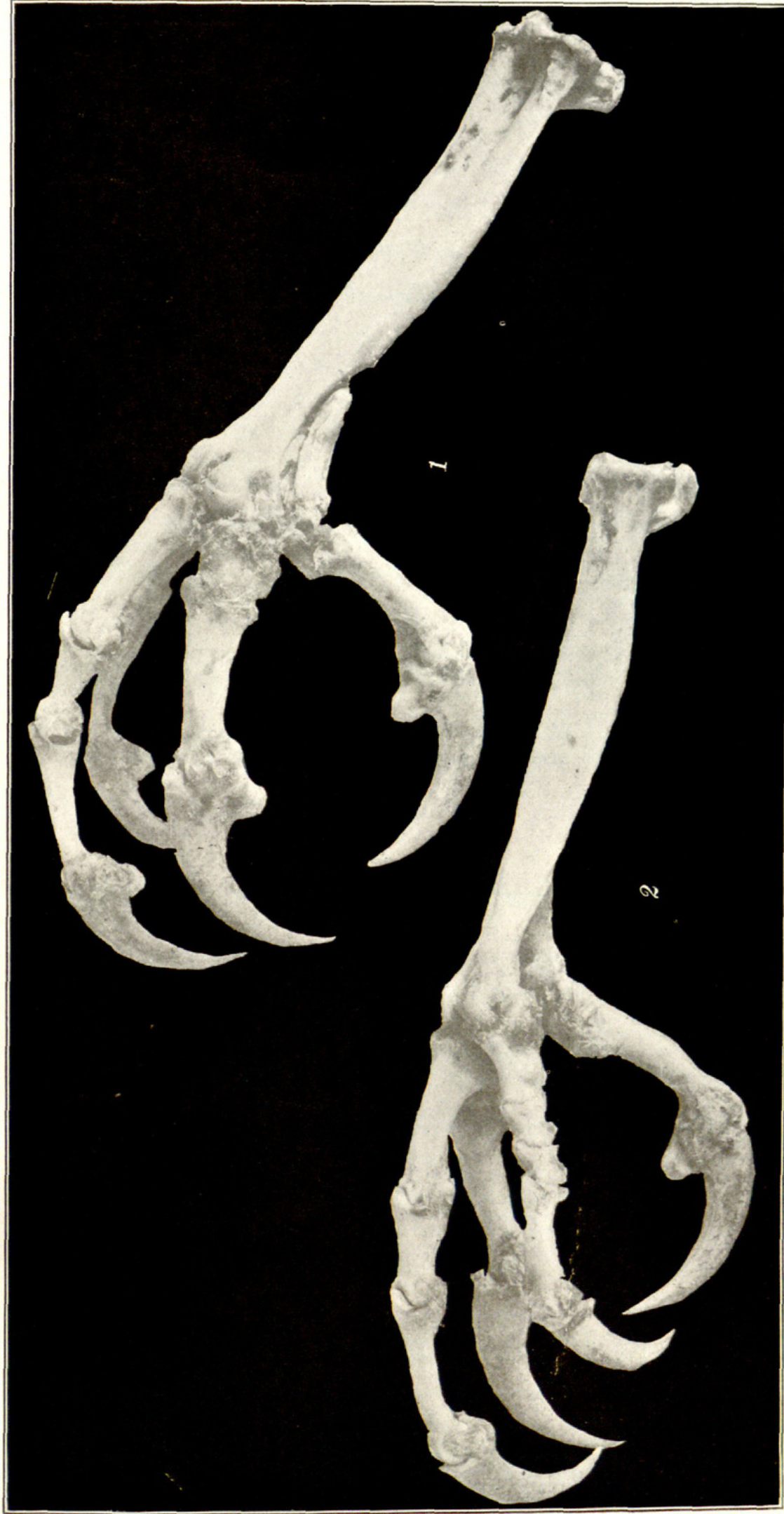

PLATE XI. FEET OF HALIAEETUS LEUCOCEPHALUS.



Shufeldt, Robert Wilson. 1919. "Osteological and other notes on the Monkey-eating Eagle of the Philippines, *Pithecopaga jefferyi* Grant." *The Philippine journal of science* 15, 31–58.

View This Item Online: <https://www.biodiversitylibrary.org/item/1125>

Permalink: <https://www.biodiversitylibrary.org/partpdf/149203>

Holding Institution

Missouri Botanical Garden, Peter H. Raven Library

Sponsored by

Missouri Botanical Garden

Copyright & Reuse

Copyright Status: Public domain. The BHL considers that this work is no longer under copyright protection.

This document was created from content at the **Biodiversity Heritage Library**, the world's largest open access digital library for biodiversity literature and archives. Visit BHL at <https://www.biodiversitylibrary.org>.